

ORIGINAL ARTICLE

# Protective effects of atorvastatin and quercetin on isoprenaline-induced myocardial infarction in rats

Mai A. Zaafan<sup>b</sup>, Hala F. Zaki<sup>a,\*</sup>, Amany I. El-Brairy<sup>b</sup>, Sanaa A. Kenawy<sup>a</sup>

<sup>a</sup> Pharmacology & Toxicology Department, Faculty of Pharmacy, Cairo University, Egypt

<sup>b</sup> Pharmacology & Toxicology Department, Faculty of Pharmacy, MSA University, Egypt

Received 29 January 2013; accepted 17 March 2013

Available online 13 April 2013

## KEYWORDS

Atorvastatin;  
Quercetin;  
Myocardial infarction;  
C-reactive protein;  
Cytokines

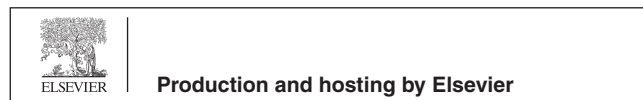
**Abstract** Myocardial infarction (MI) continues to be a major public health problem in the world. Statins exhibit cardio-protective effects by several mechanisms beyond their lipid lowering activity. Quercetin is a natural flavonoid that possesses significant anti-oxidant and anti-inflammatory activities. The present study aimed to investigate the effects of pretreatment with atorvastatin (10 mg/kg) and quercetin (50 mg/kg), as well as their combination on isoprenaline-induced MI in rats. Markers chosen to assess cardiac damage included serum activity of creatine kinase-MB (CK-MB) and serum level of cardiac troponin-I (cTn-I), as well as oxidative stress and inflammatory biomarkers including serum levels of C-reactive protein (CRP), tumor necrosis factor-alpha (TNF- $\alpha$ ), and interleukin-10 (IL-10) as well as cardiac contents of lipid peroxides, reduced glutathione (GSH), and nitrite. Furthermore, ECG monitoring and histological examinations of cardiac tissues were done. Isoprenaline increased serum CK-MB activity and cTn-I level as well as inflammatory and oxidative stress biomarkers. In addition, it produced ST-segment elevation and degenerative changes in heart tissues. Pretreatment with atorvastatin suppressed significantly the elevated levels of cTn-I, CRP, TNF- $\alpha$ , and IL-10 in serum coupled with reduction in cardiac lipid peroxides; however, it increased cardiac nitrite content. Quercetin decreased isoprenaline-induced changes in oxidative stress and inflammatory biomarkers with marked improvement in ECG and histopathologic alterations. Combination of quercetin with atorvastatin resulted in similar protective effects. In conclusion, quercetin can be regarded as a promising cardio-protective natural agent in MI alone or combined with atorvastatin.

© 2013 Production and hosting by Elsevier B.V. on behalf of Faculty of Pharmacy, Cairo University.

\* Corresponding author. Tel.: +20 224503383.

E-mail addresses: halafzaki@gmail.com, hala338@hotmail.com (H.F. Zaki).

Peer review under responsibility of Faculty of Pharmacy, Cairo University.



## 1. Introduction

Myocardial infarction (MI) is the acute condition of necrosis of the myocardium that occurs as a result of imbalance between coronary blood supply and myocardial demand.<sup>1</sup> Inflammation is a key process involved in mediating myocardial tissue damage after an ischemic event. Neutrophils infiltrate the infarcted area where they can promote myocardial

cell damage through the release of proteolytic enzymes and the production of reactive oxygen species (ROS). Inflammation may also increase the risk of recurrent ischemic events by destabilizing atherosclerotic plaques and making them prone to rupture.<sup>2</sup>

Isoprenaline, a  $\beta$ -adrenoceptor agonist, has been reported to produce MI in large doses; upon auto-oxidation, isoprenaline generates highly cytotoxic free radicals known to stimulate the peroxidation of membrane phospholipids causing severe damage to the myocardial membrane. Hence, it is widely used as a model to produce MI in rats.<sup>3,4</sup>

Atorvastatin is a cholesterol-lowering agent that acts by competitively inhibiting the rate limiting enzyme of cholesterol biosynthesis, 3-hydroxy-3-methylglutaryl-CoA (HMG-CoA) reductase. Statins prevent hypercholesterolemia, a major risk factor in the development of coronary heart disease and stroke.<sup>5</sup> In addition, recent data have indicated that statins protect the myocardium against ischemic injury.<sup>6</sup>

Quercetin is a natural anti-oxidant, producing its effects by inhibiting lipid peroxidation through blockade of the enzyme xanthine oxidase, chelating iron, and directly scavenging hydroxyl and superoxide anion radicals.<sup>7,8</sup> Quercetin has also potent anti-inflammatory potential.<sup>9</sup> In addition, it has been shown to inhibit inducible nitric oxide synthase (iNOS) expression and nitric oxide (NO) production, which further accounts for its anti-inflammatory activity.<sup>10</sup>

The present study aimed to investigate the effects of pretreatment with atorvastatin, quercetin or their combination on isoprenaline-induced MI in rats. Parameters chosen to assess myocardial damage and protective effects of test agents included serum creatine kinase-MB (CK-MB) activity as well as levels of cardiac troponin-I (cTn-I), tumor necrosis factor- $\alpha$  (TNF- $\alpha$ ), interleukin-10 (IL-10), and C-reactive protein (CRP). In addition, ECG monitoring and histologic examination of heart tissues as well as the determination of cardiac lipid peroxides, reduced glutathione (GSH), and nitrite contents were done.

## 2. Materials and Methods

### 2.1. Animals

Male Wistar albino rats weighing 150–200 g were used in the present study. They were purchased from the Egyptian Organization for Biological Products and Vaccines (Cairo, Egypt) and were allowed free access to water and standard pellet diet. Rats were kept under constant conditions with 12/12 h light/dark cycles and were housed in plastic cages in the animal house at October University for Modern Sciences and Arts (MSA University). The study was carried out according to the guidelines of the Ethics Committee, Faculty of Pharmacy, Cairo University.

### 2.2. Drugs and chemicals

Isoprenaline hydrochloride and quercetin were purchased from Sigma–Aldrich (MO, USA); whereas atorvastatin was obtained from Pfizer (Egypt). All other chemicals used were of analytical grade.

### 2.3. Induction of myocardial infarction

MI was induced in rats by subcutaneous injection of 100 mg/kg isoprenaline hydrochloride dissolved in saline once daily for two successive days. The selected route and dose were chosen from published literatures.<sup>11,12</sup>

### 2.4. Experimental design

Rats were randomly allocated into five groups ( $n = 8$ ). The first two groups received 1% Tween 80 (p.o.) for 14 days and served as normal and control groups, respectively. The remaining three groups received atorvastatin (10 mg/kg; p.o.), quercetin (50 mg/kg; p.o.), and their combination, respectively for 14 days. All groups except the normal one received isoprenaline (100 mg/kg; s.c.) in the last 2 days of treatment.

Twenty-four hours after the last treatment, animals were anesthetized with urethane (1.5 g/kg; i.p.) for ECG monitoring. Thereafter, blood samples were collected from the retro-orbital plexus for serum separation and estimation of CK-MB activity as well as cTn-I, CRP, TNF- $\alpha$ , and IL-10 levels. Rats were then sacrificed by decapitation and the hearts were rapidly isolated, washed with ice-cold saline and cut into two equal halves. One half was homogenized in phosphate buffer (pH 7.4) to prepare 10% (w/v) homogenate that was used for the estimation of cardiac lipid peroxides, GSH and nitrite contents, while the other half was preserved in 10% formalin for histologic examination.

### 2.5. ECG monitoring

Anesthetized rats were placed in the supine position on a board and ECG was recorded continuously with standard artifact free lead II (right forelimb to left hind limb). Needle electrodes were inserted subcutaneously into paw pads of each rat, and connected to Biocare ECG 101 (Shenzhen Biocare Electronics Co., Ltd., China). The ECG was measured to determine duration and amplitude of the P wave, QRS complex, and ST segment alterations.

### 2.6. Biochemical assays

The activity of CK-MB in serum was determined using Stanbio CK-MB diagnostic kit (USA). Serum troponin-I level was measured by enzyme linked immunoassay (ELISA) technique using a standard kit (Glory Science Co., Ltd, USA).

Lipid peroxidation in cardiac tissues was estimated by the determination of thiobarbituric acid reactive substances content that was evaluated as malondialdehyde (MDA) in heart homogenate using a standard kit purchased from Biodiagnostic (Egypt). Cardiac GSH content was determined using a commercial kit (Biodiagnostic, Egypt). Cardiac nitrite was determined as an index of nitric oxide (NO) content in heart homogenate using a commercial kit (Biodiagnostic, Egypt).

Serum TNF- $\alpha$  and IL-10 were determined by ELISA technique using standard kits (RayBiotech, Inc., USA). Serum CRP was measured using a specific immunoassay kit (Immunospec Corporation, CA, USA).

### 2.7. Histopathologic assessment of myocardial damage

Autopsy samples were taken from heart of rats from different groups and fixed in 10% formalin prepared in saline. Washing was done in tap water then serial dilutions of alcohol were used for dehydration. Specimens were cleared in xylene and embedded in paraffin for 24 h. Paraffin bees wax tissue blocks were prepared for sectioning at four microns by a slide microtome. Sections were deparaffinized and stained by hematoxylin and eosin (H&E) stains for histopathologic examination using the electric light microscope.

### 2.8. Statistical analysis

Data were expressed as mean  $\pm$  SEM. Comparisons between means of different groups were carried out using one-way analysis of variance (ANOVA) followed by Tukey–Kramer multiple comparisons test. The level of significance was taken as  $p < 0.05$ . SPSS statistical software package, version 16 (SPSS Inc., Chicago, IL), was used to carry out all statistical tests.

## 3. Results

### 3.1. Effect of atorvastatin, quercetin, and their combination on ECG on isoprenaline-induced myocardial infarction in rats

Subcutaneous injection of isoprenaline for two successive days induced MI represented by positive *T* wave, ST segment elevation, and a decrease in *R* wave amplitude as compared to the normal group (Fig. 1). Pretreatment with atorvastatin, quercetin or their combination resulted in a reduction in the ST segment elevation with an increase in *R* wave amplitude as compared to the isoprenaline group (Fig. 1).

### 3.2. Effect of atorvastatin, quercetin and their combination on biochemical changes that associate isoprenaline-induced myocardial infarction in rats

Isoprenaline increased serum CK-MB activity and cTn-I level by 52.5% and 349.44%, respectively as compared to the normal group. Pretreatment with atorvastatin suppressed only the elevated cTn-I level by 49.51% as compared to the isoprenaline group. Quercetin pretreatment decreased serum CK-MB activity and cTn-I level by 26% and 64.68%, respectively as compared to the isoprenaline group. Moreover, pretreatment with atorvastatin and quercetin decreased serum cTn-I level by 60.65% (Fig. 2A and B).

Isoprenaline increased cardiac MDA and nitrite contents by 39.3% and 161.2%, respectively with a parallel decrease in GSH content by 42.84% as compared to normal rats. Pretreatment with atorvastatin decreased MDA by 17.6% and increased the nitrite content by 26.9% as compared to isoprenaline group. On the other hand, pretreatment with quercetin decreased MDA and nitrite content by 21.3% and 24.0%, respectively with a parallel increase in GSH content by 43.4% as compared to the isoprenaline group, while pretreatment with atorvastatin combined with quercetin resulted in a significant decrease in MDA and nitrite contents by 18.1% and 35.6%, respectively coupled with an increase in

GSH content by 41.7% as compared to isoprenaline group (Table 1).

Serum levels of CRP, TNF- $\alpha$  and IL-10 increased significantly in rats injected with isoprenaline by 87.7%, 62.6% and 49.1%, respectively as compared to the normal group. Pretreatment of rats with atorvastatin produced a significant decrease in serum levels of CRP, TNF- $\alpha$  and IL-10 by 30.1%, 22% and 31.4%, respectively as compared to the isoprenaline group. Pretreatment with quercetin significantly decreased serum levels of CRP and TNF- $\alpha$  by 34.9% and 28%, respectively as compared to the isoprenaline group; meanwhile, pretreatment with atorvastatin combined with quercetin produced a significant decrease in serum levels of CRP, TNF- $\alpha$  and IL-10 by 38.8%, 32.8% and 37.5%, respectively as compared to the isoprenaline group (Table 2).

### 3.3. Effect of atorvastatin, quercetin or their combination on histopathologic changes that associate isoprenaline-induced myocardial infarction in rats

Hearts from rats injected with isoprenaline showed multiple focal areas of myocardial cell degeneration with edema and inflammatory cells infiltration. A marked improvement was noticed in rats pretreated with quercetin. On the other hand, pretreatment with atorvastatin or its combination with quercetin resulted in mild improvement of heart tissues as compared to the isoprenaline group (Fig. 3).

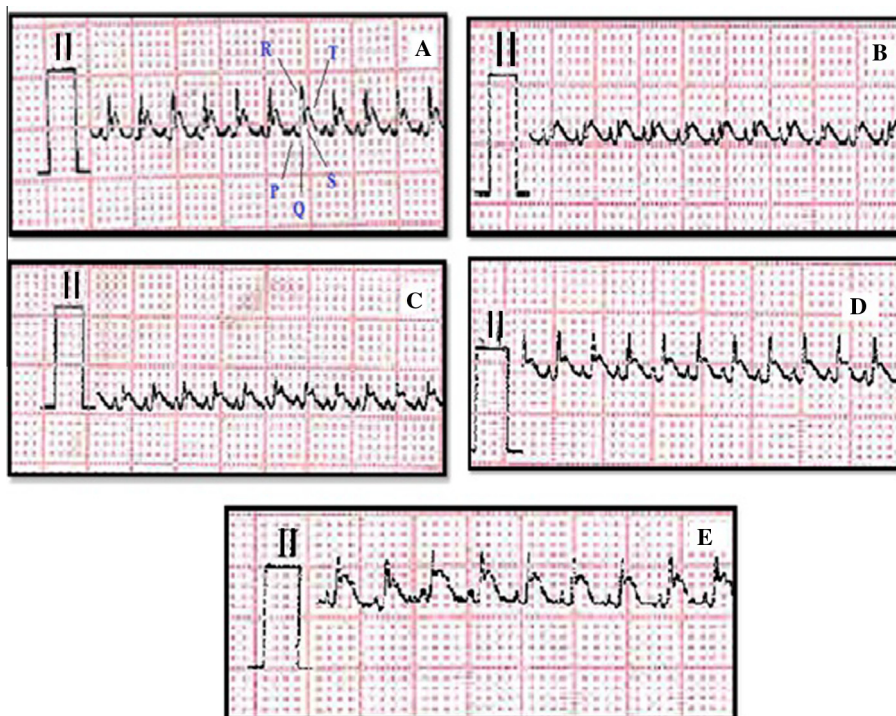
## 4. Discussion

In the current study, MI was induced in rats by subcutaneous administration of isoprenaline in a dose of 100 mg/kg for two successive days. It has been reported that isoprenaline administration in high doses to animals produces ‘infarct like’ lesions in the heart similar to those present in MI in humans.<sup>13</sup>

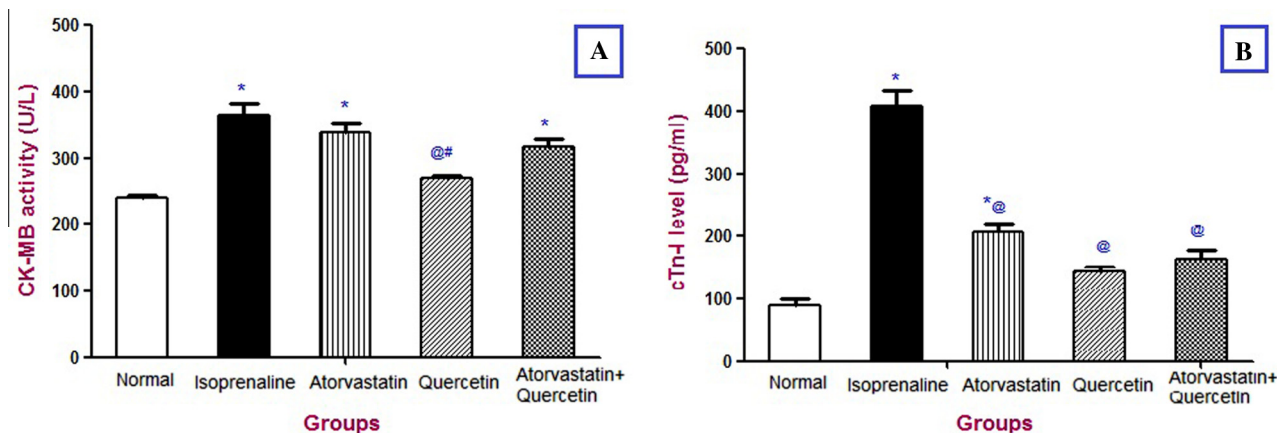
Mechanisms proposed to explain isoprenaline-induced cardiac damage are varied and include generation of highly cytotoxic free radicals, increased calcium overload, and mitochondrial injury or dysfunction.<sup>14,15</sup> Hence in the present study, the increase in cardiac MDA content (an indicator for lipid peroxidation) and the decrease in cardiac GSH content in isoprenaline group could be expected. The current results are in line with the work of other investigators.<sup>3,4,16</sup>

Isoprenaline-generated free radicals are known to initiate peroxidation of membrane-bound polyunsaturated fatty acids leading to damage of the structural and functional integrity of the myocardium with consequent changes in membrane permeability.<sup>14</sup> Myocyte death or altered membrane permeability causes the cytosolic contents to eventually enter the systemic circulation, where they may be detected as markers of the ischemic heart disease. This accounts for the elevation of serum activity of CK-MB and serum level of cTn-I in the current experiment several hours following isoprenaline administration which is in accordance with previous reports.<sup>4,13,17</sup>

Inflammation is a key process involved in mediating myocardial tissue damage after an ischemic event. In the current study, isoprenaline produced an increase in the serum levels of CRP and the pro-inflammatory cytokine TNF- $\alpha$ , an effect that is in accordance with the work of other investigators.<sup>18,19</sup> The infarcted region undergoes local necrosis and myocyte apoptosis resulting in complement activation, free radicals



**Figure 1** Lead II ECG trace pattern of: (A) Normal rat showing regular ECG pattern with defined P, QRS, and T waves; (B) Isoprenaline control rat showing positive T wave, ST segment elevation, and decreased R wave amplitude; (C) Atorvastatin-treated rat showing a decrease in ST segment elevation and an increase in R wave amplitude; (D) Quercetin-treated rat, and (E) Atorvastatin + quercetin-treated rat showing a marked decrease in ST segment elevation and an increase in R wave amplitude.



**Figure 2** Effect of oral atorvastatin (10 mg/kg), quercetin (50 mg/kg), and their combination on serum creatine kinase-MB (CK-MB) activity (A) and cardiac troponin-I (cTn-I) level (B) in isoprenaline-induced myocardial infarction in rats. Each bar represents mean  $\pm$  SEM ( $n = 8$ ). \*Significantly different from the normal group at  $p < 0.05$ . @Significantly different from the isoprenaline group at  $p < 0.05$ . #Significantly different from the atorvastatin-treated group at  $p < 0.05$ .

generation, and an accumulation of cellular debris. Phagocytosis of the resultant cellular debris by macrophages and neutrophils triggers the inflammatory cytokines as TNF- $\alpha$ .<sup>20</sup> The anti-inflammatory cytokines as IL-10 are also produced and tend to modulate the inflammatory pathways, an effect that is supported by a previous report by Pasqui et al.<sup>21</sup>

An elevation in cardiac NO content (expressed as nitrite) was observed in the present study after isoprenaline injection. Endothelium-derived NO is widely recognized as a mediator of

vasodilatation with important anti-inflammatory and anti-thrombotic properties.<sup>22</sup> In macrophages and several other cell types, inflammatory mediators increase NO production via activation of iNOS. High levels of NO production via iNOS are associated with dilated cardiomyopathy and congestive heart failure.<sup>23</sup> Indeed, isoprenaline was demonstrated to increase iNOS expression in rats.<sup>24</sup>

ECG monitoring of isoprenaline-treated rats showed positive T wave and ST segment elevation coupled with

**Table 1** Effect of oral atorvastatin, quercetin, and their combination on the cardiac contents of malondialdehyde (MDA), reduced glutathione (GSH), and nitrite in isoprenaline-induced myocardial infarction in rats.

Groups	MDA (nmol/g wet tissue)	GSH (mg/g wet tissue)	Nitrite ( $\mu\text{mol}/\text{mg}$ wet tissue)
Normal (saline; s.c.)	116.08 $\pm$ 3.20	13.33 $\pm$ 0.73	7.83 $\pm$ 0.28
Isoprenaline (100 mg/kg; s.c.)	161.71* $\pm$ 6.44	7.62* $\pm$ 0.61	20.45* $\pm$ 0.38
Atorvastatin (10 mg/kg)	133.25@ $\pm$ 6.65	9.47* $\pm$ 0.30	25.95*,@ $\pm$ 0.60
Quercetin (50 mg/kg)	127.30@ $\pm$ 7.30	10.93*,@ $\pm$ 0.31	15.55*,@,# $\pm$ 0.43
Atorvastatin + quercetin	132.47@ $\pm$ 2.87	10.80*,@ $\pm$ 0.39	13.18*,@,# $\pm$ 0.48

Each value represents mean  $\pm$  SEM ( $n = 8$ ).

\* Significantly different from normal group at  $p < 0.05$ .

@ Significantly different from isoprenaline group at  $p < 0.05$ .

# Significantly different from atorvastatin-treated group at  $p < 0.05$ .

**Table 2** Effect of oral atorvastatin, quercetin, and their combination on serum levels of C-reactive protein (CRP), tumor necrosis factor-alpha (TNF- $\alpha$ ), and interleukin-10 (IL-10) in isoprenaline-induced myocardial infarction in rats.

Groups	CRP ( $\mu\text{g}/\text{ml}$ )	TNF- $\alpha$ (pg/ml)	IL-10 (pg/ml)
Normal (saline; s.c.)	1.54 $\pm$ 0.04	82.55 $\pm$ 1.69	85.97 $\pm$ 3.38
Isoprenaline (100 mg/kg; s.c.)	2.89* $\pm$ 0.20	134.22* $\pm$ 6.14	128.15* $\pm$ 10.20
Atorvastatin (10 mg/kg)	2.02@ $\pm$ 0.09	104.73*,@ $\pm$ 3.27	87.94@ $\pm$ 7.09
Quercetin (50 mg/kg)	1.88@ $\pm$ 0.03	96.59@ $\pm$ 3.77	104.52 $\pm$ 9.28
Atorvastatin + quercetin	1.77@ $\pm$ 0.09	90.24@ $\pm$ 2.01	80.10@ $\pm$ 4.08

Each value represents mean  $\pm$  SEM ( $n = 8$ ).

\* Significantly different from the normal group at  $p < 0.05$ .

@ Significantly different from the isoprenaline group at  $p < 0.05$ .

marked decrease in *R* wave amplitude that reflect isoprenaline-induced myocardial ischemia and infarction. ECG pattern alterations by isoprenaline were previously demonstrated by previous investigators.<sup>19,25</sup> Histopathologic examination of isoprenaline-treated rats revealed infiltration of inflammatory cells along with myocyte degeneration. These results are in accordance with previous studies.<sup>4,13,16</sup> These observations along with the present biochemical changes in cardiac enzymes and cytokines level confirm the severity of myocardial injury.

Pretreatment with atorvastatin (10 mg/kg) attenuated the cardiac damage caused by isoprenaline. The drug decreased ST-segment elevation with marked increase in *R*-wave amplitude. Atorvastatin also produced a significant decrease in serum cTn-I level. The current results support those of other investigators who reported a cardioprotective effect of atorvastatin.<sup>19,26,27</sup> Atorvastatin changes in ECG and cardiac enzymes were coupled by a reduction in lipid peroxidation in heart tissue through the significant decrease in heart MDA content. Similar results were reported by Mahfouz and Kummerow.<sup>28</sup>

Pretreatment with atorvastatin showed also a marked decrease in the serum levels of CRP, TNF- $\alpha$ , and IL-10 which could be attributed to atorvastatin documented anti-inflammatory properties.<sup>6,29,30</sup> Moreover, atorvastatin protective effects in MI may be mediated by the modulation of fibrinolysis by reducing the levels of plasminogen activator inhibitor-1.<sup>19</sup> These changes were coupled with a significant increase in cardiac nitrite content. Previous studies demonstrated the ability of statins to upregulate eNOS activity and NO production by increasing eNOS mRNA stability.<sup>31,32</sup>

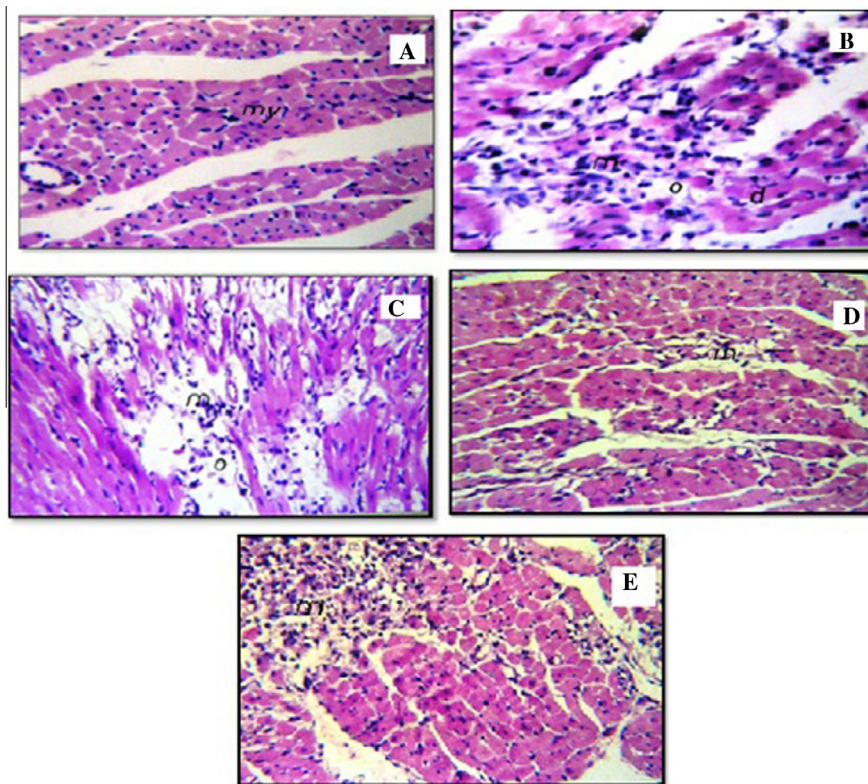
Pretreatment with quercetin (50 mg/kg) produced a marked protection against isoprenaline-induced myocardial damage.

Indeed, the suppression of MI by quercetin was reflected in the current investigation through the suppression of ST-segment elevation and the marked increase in *R* wave amplitude upon ECG monitoring as compared to the isoprenaline group. These results are in agreement with previous studies.<sup>25,33</sup> In addition, quercetin decreased the serum CK-MB activity and cTn-I level when compared to the isoprenaline group. These findings are in harmony with previous reports.<sup>34-36</sup>

Moreover, results of the current study reflected the ability of quercetin to ameliorate isoprenaline-induced changes in oxidative stress biomarkers, which is in agreement with the work of previous investigators.<sup>33,36</sup> These results are in harmony with previous reports which stated that the biological actions of quercetin are, in part, connected to its anti-oxidant properties which are mainly due to its ability to scavenge ROS and to chelate transition metal ions.<sup>35,37</sup> Moreover, quercetin protective effects could be also related to its ability to maintain heart calcium content and prevent isoprenaline-induced increase in heart calcium.<sup>38</sup> The present findings were coupled by a reduction in cardiac nitrite content. A possible explanation for the decrease in NO production by quercetin may be mediated by its ability to inhibit iNOS expression through inhibition of nuclear factor-kappa B pathway, which further accounts for its anti-inflammatory potential.<sup>10</sup>

The anti-inflammatory effect of quercetin was apparent by the marked decrease in serum levels of CRP and TNF- $\alpha$ , which is in agreement with previous studies.<sup>9,39</sup> On the other hand, quercetin mono-therapy failed to produce a significant decrease in serum IL-10 level. Further studies may be required to explain this matter.

In the current study, pretreatment with atorvastatin and quercetin together showed marked cardioprotective effects re-



**Figure 3** Effect of oral atorvastatin (10 mg/kg), quercetin (50 mg/kg), and their combination on cardiac histopathologic changes in isoprenaline-induced myocardial infarction in rats. (A) Section in a normal rat showing normal architecture of the heart tissue, being composed of muscle cells, cardiomyocytes (my), with one centrally placed nucleus; (B) Isoprenaline control rat showing multiple focal areas of myocardial cell degeneration (d) with edema (o) and inflammatory cells infiltration; (C) Atorvastatin-treated rat showing edema with mild inflammatory cells infiltration in focal manner at the myocardium; (D) Quercetin-treated rat showing a noticeable preservation from the deleterious effects of isoprenaline; (E) Atorvastatin + quercetin-treated rat showing a decrease in focal areas of edema and inflammatory cells infiltration as compared to the isoprenaline control rat.

flected by decreased serum cTn-I level, improved ECG alterations coupled by decreased oxidative stress and all inflammatory markers. Histopathologic examination of cardiac tissues correlated with the observed biochemical and ECG changes. Such effects can be explained by previously reported anti-oxidant and anti-inflammatory potentials of both quercetin and atorvastatin that were more apparent upon their combination together.<sup>6,9,28,36</sup>

## 5. Conclusions

In conclusion, the present study revealed that quercetin and atorvastatin pretreatment attenuated oxidative stress and inflammatory reactions as well as declined tissue damage in isoprenaline-induced MI in rats. Further experimental and clinical studies may be needed to verify the cardioprotective effects of atorvastatin and quercetin.

## 6. Conflict of interest

None.

## Acknowledgment

The authors are very grateful to Dr. Adel M. Bakeer, Professor of Pathology, Faculty of Veterinary Medicine, Cairo University for examining and interpreting histopathologic aspects of this study.

## References

1. de Bono DP, Simoons ML, Tijssen J, Arnold AE, Betriu A, Burgersdijk C, et al. Effect of early intravenous heparin on coronary patency, infarct size, and bleeding complications after alteplase thrombolysis: results of a randomised double blind European cooperative study group trial. *Br Heart J* 1992;**67**: 122–8.
2. Jordan JE, Zhao ZQ, Vinten-Johansen J. The role of neutrophils in myocardial ischemia-reperfusion injury. *Cardiovasc Res* 1999;**43**:860–78.
3. Panda VS, Naik SR. Evaluation of cardioprotective activity of Ginkgo biloba and Ocimum sanctum in rodents. *Altern Med Rev* 2009;**14**:161–71.
4. Kannan MM, Quine SD. Ellagic acid inhibits cardiac arrhythmias, hypertrophy and hyperlipidaemia during myocardial infarction in rats. *Metabolism* 2013;**62**:52–61.

5. Kapur NK, Musunuru K. Clinical efficacy and safety of statins in managing cardiovascular risk. *Vasc Health Risk Manag* 2008;**4**:341–53.
6. Balakumar P, Mahadevan N. Interplay between statins and PPARs in improving cardiovascular outcomes: a double-edged sword? *Br J Pharmacol* 2012;**165**:373–9.
7. Takizawa S, Fukuyama N, Hirabayashi H, Kohara S, Kazahari S, Shinohara Y, et al. Quercetin, a natural flavonoid, attenuates vacuolar formation in the optic tract in rat chronic cerebral hypoperfusion model. *Brain Res* 2003;**980**:156–60.
8. Heo HJ, Lee CY. Protective effects of quercetin and vitamin C against oxidative stress-induced neurodegeneration. *J Agric Food Chem* 2004;**52**:7514–7.
9. Kleemann R, Verschuren L, Morrison M, Zadelara S, Van Erk PY, Wielinga PY, et al. Anti-inflammatory, anti-proliferative and anti-atherosclerotic effects of quercetin in human in vitro and in vivo models. *Atherosclerosis* 2011;**218**:44–52.
10. Comalada M, Camuesco D, Sierra S, Ballester I, Xaus J, Galvez J, et al. In vivo quercitrin anti-inflammatory effect involves release of quercetin, which inhibits inflammation through down-regulation of the NF-kappa B pathway. *Eur J Immunol* 2005;**35**:584–92.
11. Priscilla DH, Prince PS. Cardioprotective effect of gallic acid on cardiac troponin-T, cardiac marker enzymes, lipid peroxidation products and antioxidants in experimentally induced myocardial infarction in Wistar rats. *Chem Biol Interact* 2009;**179**:118–24.
12. Kumaran KS, Prince PS. Caffeic acid protects rat heart mitochondria against isoproterenol-induced oxidative damage. *Cell Stress Chaperon* 2010;**15**:791–806.
13. Vennila L, Pugalendi KV. Protective effect of sesamol against myocardial infarction caused by isoproterenol in Wistar rats. *Redox Rep* 2010;**15**:36–42.
14. Dhalla N, Yates J, Naimark B. *Cardiotoxicity of catecholamines and related agents* Cardiovascular Toxicology. 2nd ed. New York: Raven Press; 1992. p. 239–82.
15. Rathore N, Kale M, John S, Bhatnagar D. Lipid peroxidation and antioxidant enzymes in isoproterenol induced oxidative stress in rat erythrocytes. *Indian J Physiol Pharmacol* 2000;**44**:161–6.
16. Gayathri V, Ananthi S, Chandronitha C, Ramakrishnan G, Sundaram RL, Vasanthi HR. Cardioprotective effect of Nerium Oleander flower against isoproterenol-induced myocardial oxidative stress in experimental rats. *J Cardiovasc Pharmacol Ther* 2011;**16**:96–104.
17. Buja A. Modulation of the myocardial response to ischemia. *Lab Invest* 1998;**78**:1345–73.
18. Cusack MR, Marber MS, Lambiase PD, Bucknall CA, Redwood SR. Systemic inflammation in unstable angina is the result of myocardial necrosis. *J Am Coll Cardiol* 2002;**39**:1917–23.
19. Tawfik MK, Ghattas MH, Abo-Elmatty DM, Abdel-Aziz NA. Atorvastatin restores the balance between pro-inflammatory and anti-inflammatory mediators in rats with acute myocardial infarction. *Eur Rev Med Pharmacol Sci* 2010;**14**:499–506.
20. Frangogiannis NG, Wayne-Smith C, Entman ML. The inflammation response in myocardial infarction. *Cardiovasc Res* 2002;**53**:31–47.
21. Pasqui AL, Direnzo M, Auteri A, Puccetti L. Cytokines in coronary syndromes. *Int J Cardiol* 2005;**105**:355–6.
22. Landmesser U, Hornig B, Drexler H. Endothelial function: a critical determinant in atherosclerosis? *Circulation* 2004;**109**(Suppl. ):27–33.
23. Ishibashi Y, Takahashi N, Tokumaru A, Karino K, Sugamori T, Sakane T, et al. Activation of inducible NOS in peripheral vessels and outcomes in heart failure patients. *J Card Fail* 2008;**14**:724–31.
24. Buttros JB, Bergamaschi CT, Ribeiro DA, Fracalossi AC, Campos RR. Cardioprotective actions of ascorbic acid during isoproterenol-induced acute myocardial infarction in rats. *Pharmacology* 2009;**84**:29–37.
25. Prince PS, Sathya B. Pretreatment with quercetin ameliorates lipids, lipoproteins and marker enzymes of lipid metabolism in isoproterenol treated cardiotoxic male Wistar rats. *Eur J Pharmacol* 2010;**635**:142–8.
26. Trivedi CJ, Balaraman R, Majithiya JB, Bothara SB. Effect of atorvastatin treatment on isoproterenol-induced myocardial infarction in rats. *Pharmacology* 2006;**77**:25–32.
27. Garjani A, Andalib S, Biabani S, Soraya H, Doustar Y, Garjani A, et al. Combined atorvastatin and coenzyme Q10 improve the left ventricular function in isoproterenol-induced heart failure in rat. *Eur J Pharmacol* 2011;**666**:135–41.
28. Mahfouz MM, Kummerow FA. Atorvastatin reduces the plasma lipids and oxidative stress but did not reverse the inhibition of prostacyclin generation by aortas in streptozotocin diabetic rats. *Prostaglandins Other Lipid Mediators* 2005;**76**:59–73.
29. Davignon J. Cardioprotective and other emerging effects of statins. *Int J Clin Pract* 2004;**143**:49–57.
30. Sun YM, Tian Y, Li X, Liu YY, Wang LF, Li J, et al. Effect of atorvastatin on expression of IL-10 and TNF-alpha m-RNA in myocardial ischemia-reperfusion injury in rats. *Biochem Biophys Res Commun* 2009;**382**:336–40.
31. Laufs U, La-Fata V, Plutzky J, Liao JK. Upregulation of endothelial nitric oxide synthase by HMG CoA reductase inhibitors. *Circulation* 1998;**97**:1129–35.
32. El-Sisi AA, Hegazy SK, Salem KA, Abdelkawy KS. Atorvastatin improves erectile dysfunction in patients initially irresponsive to sildenafil by the activation of endothelial nitric oxide synthase. *Int J Impot Res* 2013 Epub ahead of print.
33. Panda S, Kar A, Banerjee T, Sharma N. Combined effects of quercetin and atenolol in reducing isoproterenol-induced cardiotoxicity in rats: possible mediation through scavenging free radicals. *Cardiovasc Toxicol* 2012;**12**:235–42.
34. Ikizler M, Erkasap N, Dernek S, Kural T, Kaygisiz Z. Dietary polyphenol quercetin protects rat hearts during reperfusion: enhanced antioxidant capacity with chronic treatment. *Anadolu Kardiyol Derg* 2007;**7**:404–10.
35. Punithavathi VR, Prince PS. Combined effects of quercetin and alpha-tocopherol on lipids and glycoprotein components in isoproterenol induced myocardial infarcted Wistar rats. *Chem Biol Interact* 2009;**181**:322–7.
36. Liu H, Zhang L, Lu S. Evaluation of antioxidant and immunity activities of quercetin in isoproterenol-treated rats. *Molecules* 2012;**17**:4281–91.
37. Sestili P, Guidarelli A, Dacha M, Cantoni O. Quercetin prevents DNA single strand breakage and cytotoxicity caused by tert-butylhydroperoxide: free radical scavenging versus iron chelating mechanism. *Free Radical Biol Med* 1998;**25**:196–200.
38. Punithavathi VR, Prince PS. The cardioprotective effects of a combination of quercetin and  $\alpha$ -tocopherol on isoproterenol-induced myocardial infarcted rats. *J Biochem Mol Toxicol* 2011;**25**:28–40.
39. Wadsworth TL, Koop DR. Effects of the wine polyphenolics quercetin and resveratrol on pro-inflammatory cytokine expression in RAW 264.7 macrophages. *Biochem Pharmacol* 1999;**57**:941–9.