



## Rutin Ameliorates Hepatic Fibrosis via Targeting Hepatic Stellate Cells' Activation, Proliferation and Apoptosis

Walaa H. El-Maadawy, S. H. Seif el-Din, S. M. Ezzat, O. A. Hammam, M. M. Safar, S. Saleh & N. M. El-Lakkany

To cite this article: Walaa H. El-Maadawy, S. H. Seif el-Din, S. M. Ezzat, O. A. Hammam, M. M. Safar, S. Saleh & N. M. El-Lakkany (2021) Rutin Ameliorates Hepatic Fibrosis via Targeting Hepatic Stellate Cells' Activation, Proliferation and Apoptosis, *Journal of Herbs, Spices & Medicinal Plants*, 27:3, 322-341, DOI: [10.1080/10496475.2021.1911905](https://doi.org/10.1080/10496475.2021.1911905)

To link to this article: <https://doi.org/10.1080/10496475.2021.1911905>



Published online: 30 Apr 2021.



Submit your article to this journal [↗](#)



Article views: 29



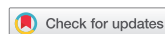View related articles [↗](#)



View Crossmark data [↗](#)



ARTICLE



## Rutin Ameliorates Hepatic Fibrosis via Targeting Hepatic Stellate Cells' Activation, Proliferation and Apoptosis

Walaa H. El-Maadawy<sup>a</sup>, S. H. Seif el-Din <sup>a</sup>, S. M. Ezzat<sup>b,c</sup>, O. A. Hammam<sup>d</sup>,  
M. M. Safar<sup>e,f</sup>, S. Saleh<sup>e</sup>, and N. M. El-Lakkany <sup>a</sup>

<sup>a</sup>Pharmacology Department, Theodor Bilharz Research Institute, Giza, Egypt; <sup>b</sup>Pharmacognosy Department, Faculty of Pharmacy, Cairo University, Cairo, Egypt; <sup>c</sup>Pharmacognosy Department, Faculty of Pharmacy, October University for Modern Sciences and Arts, Giza, Egypt; <sup>d</sup>Pathology Department, Theodor Bilharz Research Institute, Giza, Egypt; <sup>e</sup>Pharmacology and Toxicology Department, Faculty of Pharmacy, Cairo University, Cairo, Egypt; <sup>f</sup>Pharmacology and Biochemistry Department, Faculty of Pharmacy, The British University in Egypt, Cairo, Egypt

### ABSTRACT

Despite rutin, extracted from black mulberry, has several pharmacological activities, its exact effect against hepatic fibrosis remains incompletely identified. Accordingly, this study investigates whether rutin is a promising candidate for treating hepatic fibrosis and to clarify its underlying antifibrotic mechanisms *in vitro* and *in vivo*. *In vitro* studies were performed on hepatic stellate cell line (HSC-T6) whereas liver fibrosis was established in rats via chronic thioacetamide (TAA)-intoxication. Rats were divided into (i) normal, (ii) TAA-intoxicated rats; TAA-intoxicated rats treated with (iii) silymarin or (iv) rutin. Levels of ALT, AST, platelet-derived growth factor-BB (PDGF-BB), tissue inhibitor metalloproteinases type-1 (TIMP-1), hydroxyproline and expression of proliferating cellular nuclear antigen (PCNA) together with histological changes were examined. Activities of rutin on TGF- $\beta$ 1,  $\alpha$ -smooth muscle actin ( $\alpha$ -SMA) and caspase-3 were measured *in vitro* and *in vivo*. Rutin exhibited no marked HSC-T6 cell death ( $IC_{50} = 460 \mu\text{g}\cdot\text{ml}^{-1}$ ), however, it showed reduction in HSCs activation (low TGF- $\beta$ 1 level and  $\alpha$ -SMA positive cells) and induced apoptosis (high caspase-3 positive cells). Rutin also ameliorated liver functions, reduced hepatic levels of PDGF-BB, TGF- $\beta$ 1, TIMP-1, hydroxyproline and restored PCNA, together with attenuation in fibrosis score (S1 vs S4). Rutin could be a promising candidate for treating hepatic fibrosis through down-regulation of HSCs activation and induction of apoptosis.

### ARTICLE HISTORY



Received 10 April 2020

### KEYWORDS

Rutin; fibrosis markers; hepatic stellate-T6; *in vivo*; *in vitro*

## Introduction

Hepatic fibrosis is a naturally occurring wound healing response toward chronic liver diseases including viral hepatitis (B and C), alcoholic or non-alcoholic fatty liver, parasitic and autoimmune diseases as well as drug toxicity.<sup>[1]</sup> It is well established that the key fibrogenic cells in hepatic

**CONTACT** S. H. Seif el-Din  [s.seifeldin@tbri.gov.eg](mailto:s.seifeldin@tbri.gov.eg), [sayedseifeldin@hotmail.com](mailto:sayedseifeldin@hotmail.com)  Pharmacology Department, Theodor Bilharz Research Institute, 1 El-Nile St. Warak El-Hadar Imbaba P.O. Box 30, Giza, .12411, Egypt.

fibrogenesis are the activated hepatic stellate cells (HSCs), although other cells can make significant contributions.<sup>[2]</sup> Following hepatic injury, HSCs undergo a process known as activation where they trans-differentiate into a highly proliferative, contractile, and fibrogenic cell, thereafter they migrate to the site of injury producing extracellular matrix (ECM), cytokines and growth factors thus leading to the promotion of fibrosis.<sup>[3]</sup> As well, clearance of activated HSCs was also shown to be an important contributor in the reversal of hepatic fibrosis, through three main pathways: apoptosis,<sup>[4]</sup> senescence,<sup>[5]</sup> or reversion to a quiescent phenotype.<sup>[6]</sup>

Despite the advances in clarification of the molecular mechanisms, the underlying sources and mediators of fibrosis progression, no clinical translation has been attained so far. Medicinal plants have gained popularity worldwide as antifibrotic agents<sup>[7]</sup> owing to being recognized as safe alternatives to synthetic drugs, fitting into the image of a harmless kind of treatment by entailing less toxicity, better therapeutic effect, good patient compliance and cost effectiveness.<sup>[8]</sup>

Polyphenols are considered one of the most extensively studied phytochemicals due to their abundance in fruits, vegetables, cereals and beverages.<sup>[8]</sup> Mulberry fruits (*Morus alba* L.) are rich in phenolic compounds, including flavonoids, anthocyanins and carotenoids, where rutin a well-known flavonoidal glycoside is present in the highest quantity.<sup>[9]</sup> Rutin is reported to exert several pharmacological activities including anti-allergic, anti-inflammatory, antitumor, antibacterial and antiviral properties. In addition, few articles studied the hepatoprotective effects of rutin against nonalcoholic fatty liver disease<sup>[10]</sup> and ethanol-induced toxicity.<sup>[11]</sup> Besides, to the best of the authors' knowledge, limited number of articles documented the antiproliferative activities of flavonoids, other than rutin, on HSC-T6 cell line.<sup>[12,13]</sup>

A number of hepatotoxins are employed for preclinical induction of liver fibrosis, where chronic intoxication with thioacetamide (TAA) was established as a reliable and reproducible experimental model perfectly mimic human chronic hepatic diseases.<sup>[14]</sup> This could be due to its high selectivity to induce various grades of liver damage including fibrosis,<sup>[15]</sup> cirrhosis,<sup>[14]</sup> hepatic necrosis/apoptosis<sup>[16]</sup> and most importantly HSC activation.<sup>[17]</sup> Accordingly, this study was oriented to investigate the potential antifibrotic efficacy of rutin, attempted to provide insights on its exact mechanism of actions on HSCs both *in vitro*, and in TAA-induced liver fibrosis.

## Materials and Methods

### Plant Materials

Black mulberry (*Morus nigra*) fruits were obtained in spring 2014, from the Experimental Station of Medicinal and Aromatic Plants, Pharmacognosy

Department, Faculty of Pharmacy, Cairo University. It was kindly identified in Botany Department, Faculty of Science, Cairo University, Giza, Egypt. A voucher specimen (2014067) was kept in the herbarium of the Pharmacognosy Department, Faculty of Pharmacy, Cairo University.

### ***Isolation and Extraction of Rutin***

Fresh black mulberry fruits (1 kg) were cut into small pieces and percolated with 2 L of 80% ethanol for 24 h. The extraction was repeated twice and the ethanolic extract was evaporated under reduced pressure at 50°C using rotary evaporator to yield 85.64 g. Fifty grams of the extract were fractionated over Diaion HP column using 100% water, 50% methanol (MeOH) in water and 100% MeOH. The fractions were screened on thin layer chromatography (TLC) using ethyl acetate-MeOH-water-formic acid (10:1.6:1.2:0.5 v/v/v/v). Thirteen grams of 50% MeOH produced a major spot, which was yellow in visible light and dull under UV (after spraying with  $\text{AlCl}_3$ , Rf 0.54). This fraction was then purified over several Sephadex LH 20 columns using MeOH-water (1:1 v/v) yielding 5 g of rutin compound.

### ***Purity Testing of Rutin Using HPLC Analysis***

The isolated rutin (5 mg) was dissolved in 5 mL methanol to obtain a concentration of  $1 \text{ mg}\cdot\text{mL}^{-1}$ . The solution was filtered through  $0.45 \mu\text{M}$  membrane filter and subjected to HPLC analysis using an Agilent 1100 series HPLC system (Agilent Technologies, Palo Alto, CA), equipped with a quaternary pump G1311A, degasser G1322A, UV detector and an Agilent ChemStation software. Separation was carried out on LiChrospher® RP-C18 endcapped ( $5 \mu\text{m}$ ) (Merck, Germany). The mobile phase used was acetonitrile (solvent A) and 0.3% phosphoric acid in water (solvent B). Gradient elution was carried out at room temperature and at a flow rate of  $1 \text{ mL}\cdot\text{min}^{-1}$  as follows: 0–15 min 10–40% A in B, 15–20 min 40–70% A in B, 20–22 min 70–10% A in B. Measurements were made with an injection volume of  $20 \mu\text{L}$  and UV detection at 325 nm.

### ***In Vitro Studies***

#### ***Effect of Rutin on HSCs-proliferation, Activation and Apoptosis***

An immortalized rat hepatic stellate cell line (HSC-T6) was used. Rutin was dissolved in a small volume of dimethyl sulfoxide (DMSO) equivalent to 0.1% final concentration (v/v). The solution was filtered through a  $0.22\text{-}\mu\text{m}$  membrane and aliquots were stored at  $-20^\circ\text{C}$  protected from light. Micro cultures of  $5 \times 10^3$  HSCs were cultured in 96-well tissue culture plates (Nunc, Roskilde, Denmark) in  $200 \mu\text{L}$  DMEM with 10% FBS. After 24 h, cells were treated with

different concentrations of rutin ( $0\text{--}500\ \mu\text{g}\cdot\text{mL}^{-1}$ ) for 24 and 48 h and cell survival ratios corresponding to untreated cells were examined. Each test was performed in triplicate. The anti-proliferative effect of rutin on HSCs was assessed using sulforhodamine base (SRB) assay and expressed in terms of the  $\text{IC}_{50}$  value. HSCs activation was assessed via determining of TGF- $\beta$ 1 concentrations in culture media using the commercial ELISA kit according to the manufacturer's instructions and immunocyto staining of HSCs with  $\alpha$ -SMA; moreover, HSCs apoptosis was assessed using caspase-3 immunocyto staining.

### ***Effect of Rutin on Hepatocytes Viability/cytotoxicity***

Primary hepatocytes were freshly isolated from rats by a two-step portal collagenase perfusion of the liver.<sup>[18]</sup> Hepatocytes cell viability was assessed by trypan blue dye exclusion. Cytotoxicity of rutin on isolated rat hepatocytes was assessed by thiazolyl blue tetrazolium bromide (MTT) where primary hepatocytes ( $5 \times 10^3$ ) were cultured in 96-wells tissue culture plates and treated with the previously mentioned concentrations of rutin for 24- and 48-h. MTT solution ( $20\ \mu\text{L}$  of  $0.5\ \text{mg}\cdot\text{mL}^{-1}$ ) was added to each well and incubated for another 4 h at  $37^\circ\text{C}$ . The MTT-formazan generated by viable cells was measured with an ELISA reader at 570 nm.

## ***In Vivo Studies***

### ***Animals***

Adult male Sprague-Dawley rats, weighing 250–300 g, obtained from the animal house of Theodor Bilharz Research Institute (TBRI), Giza, Egypt, were housed under an environmentally controlled room at  $20\text{--}22\ ^\circ\text{C}$ , 12 h light/dark cycles and 50–60% humidity with free access to food and water *ad libitum* throughout the acclimatization and experimental periods. All the animal experiments comply with the Guide for Care and Use of Laboratory Animals published by the US National Institutes of Health (NIH Publication No. 85–23, revised 2011) and were approved by the Ethical Review Board of TBRI as well as the research ethics committee for experimental and clinical studies at Faculty of Pharmacy, Cairo University (PT: 559).

### ***Experimental Design***

Thirty-two rats were randomly divided into four groups, eight rats each: (i) normal control; (ii) TAA-intoxicated rats injected intraperitoneally (i.p.) with TAA in a dose of  $200\ \text{mg}\cdot\text{kg}^{-1}$  twice weekly for 12 weeks.<sup>[19]</sup> TAA-intoxicated rats administered (iii) silymarin ( $50\ \text{mg}\cdot\text{kg}^{-1}$ <sup>[20]</sup>) or (iv) rutin ( $50\ \text{mg}\cdot\text{kg}^{-1}$ <sup>[21]</sup>) via oral gavage at daily doses for 8 weeks starting from the 5<sup>th</sup> week of TAA-intoxication, where an apparent stage of fibrosis (S2) was verified, guided by histopathological examination of hepatic tissues. Forty-eight h after the last treatment, rats were killed by decapitation after an i.p. injection of ketamine

(80 mg.kg<sup>-1</sup>). Blood samples were collected, centrifuged at 1,500 g; sera were separated and then stored at -80°C for assessment of liver functions. Moreover, livers were excised, weighed and subsequently divided into two portions, the first was fixed in formalin for histopathological and immunohistochemical examinations. The second portion was washed with 0.9% ice-cold saline and stored at - 80 °C for assessment of oxidative stress and fibrosis markers as well as hydroxyproline (HP) contents.

#### ***Assessment of Liver Function and Oxidative Stress Markers***

Serum alanine (ALT) and aspartate (AST) aminotransferases (Spectrum, Egypt), the level of reduced glutathione (GSH) and the extent of lipid peroxidation expressed as malondialdehyde (MDA) formation in liver homogenates (Biodiagnostic, Egypt) were determined spectrophotometrically using the commercially available kits.

#### ***Assessment of Liver Fibrosis Markers***

Tissue inhibitor matrix metalloproteinases, type-1 (TIMP-1), transforming growth factor-β1 (TGF-β1) and platelet-derived growth factor-B (PDGF-B) levels were measured in liver tissue homogenates by commercial ELISA kits (R & D system, MN, USA). The content of HP was determined in liver tissue samples as previously described.<sup>[22]</sup>

#### ***Liver Histology, Fibrosis Grade and Immunohistochemical Examinations***

Liver specimens were fixed in 10% formalin and embedded in paraffin blocks. Tissue sections were stained with hematoxylin-eosin (H&E) (4 μm-thickness) and Sirius red (20 μm-thickness) for analysis of overall liver histology and collagen distribution respectively. Collagen was quantified using imaging analysis software (Axiovision L.E. 4.8; Carl Zeiss MicroImaging, Jena, Germany). Briefly, paraffin sections were stained in 0.1% Sirius red F3B (SR) in saturated picric acid. The red-stained area (mm<sup>2</sup>) was measured in five consecutive fields (x 50) and a numerical scoring system for morphometric analysis of hepatic fibrosis score was used.<sup>[23]</sup> Additionally, liver sections were immunohistochemically stained for caspase-3, PCNA and α-SMA with a horseradish-peroxidase complex kit (Abcam Inc, UK). The percent of positively stained brown nuclei (PCNA) or brown cytoplasm (α-SMA and caspase-3) was examined in 10 microscopic fields (at x 400 under Zeiss light microscopy, Jena, Germany).

#### ***Statistical Analysis***

Data are expressed as mean ± SEM. Statistical analysis was performed using one-way ANOVA test followed by either Dunnett's or Tukey's *post hoc* test for

multiple comparisons (GraphPad Software, San Diego, CA, USA, version 5.03). The difference in fibrosis stages between groups was analyzed by Kruskal-Wallis test followed by Dunn's multiple comparisons test. Differences were considered significant at  $P < .05$ .

## Results

### *Spectroscopic Data, Identification and Purity of Rutin*

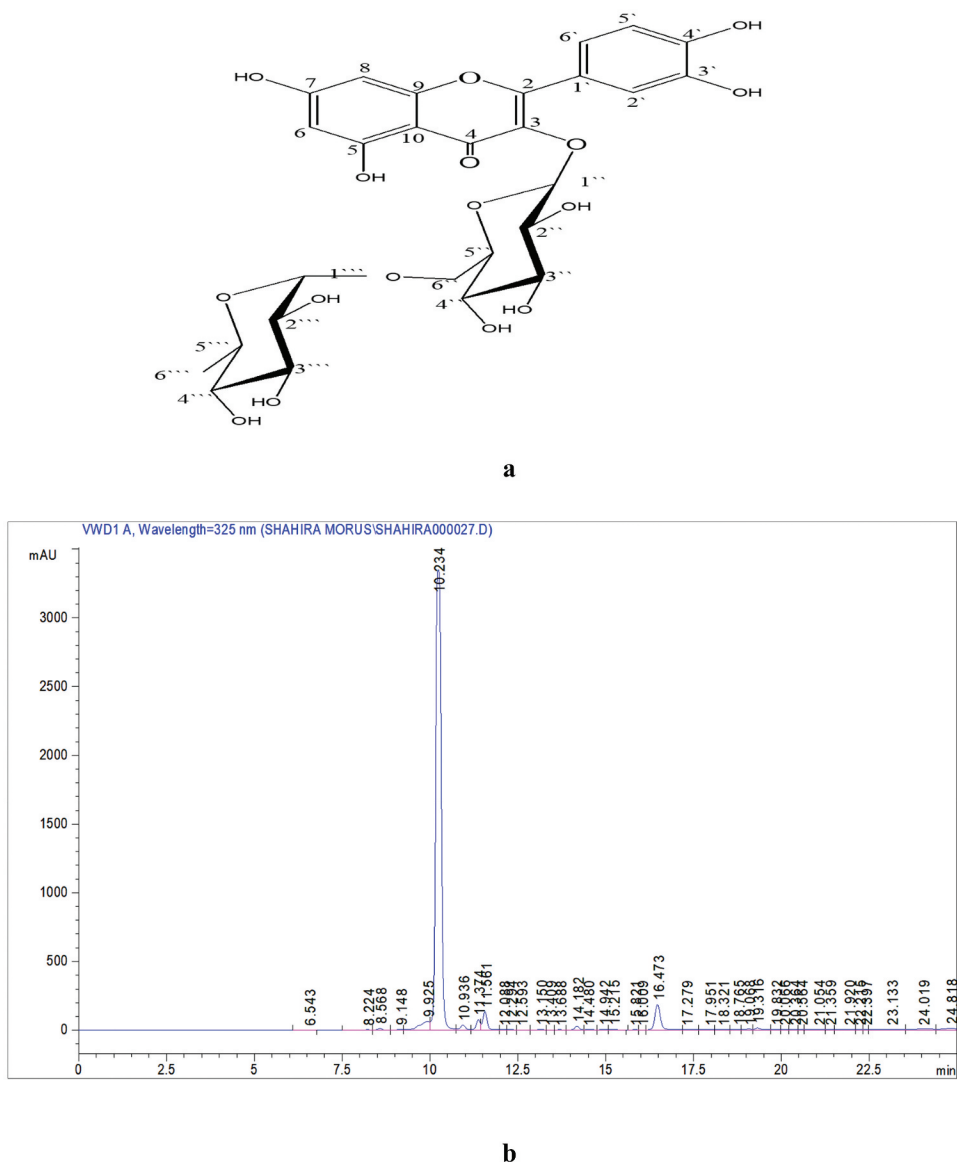
$^1\text{H}$ NMR spectrum showed the characteristic signals for rutin (Table 1), which was confirmed by the UV data (Table 2). The structure of the isolated and identified rutin is shown in Fig. 1a. HPLC analysis of the isolated rutin showed that its purity was reached to be 99.4% (Fig. 1b).

**Table 1.**  $^1\text{H}$ NMR and  $^{13}\text{C}$ NMR chemical shifts ( $\delta$  ppm) of the isolated rutin (DMSO- $d_6$  for  $^1\text{H}$  400 and 100 MHz for  $^{13}\text{C}$ ).

Position	$\delta_{\text{H}}$ ppm	$\delta_{\text{C}}$ ppm
2	-	158.2
3	-	136.0
4	-	178.9
5	-	161.8
6	6.14 d (1.8)	99.6
7	-	165.6
8	6.44 d (1.8)	94.2
9	-	158.9
10	-	104.5
1'	-	122.6
2'	7.49 br.s	116.7
3'	-	144.9
4'	-	148.5
5'	6.80 d (7.8)	115.9
6'	7.54 dd (1.8, 7.8)	122.9
1''	5.51 d (7.2)	100.8
2''	-	74.5
3''	-	76.5
4''	-	72.1
5''	-	76.2
6''	-	66.6
1'''	5.10 d (2.1)	101.1
2'''	-	71.0
3'''	-	71.5
4'''	-	73.0
5'''	-	68.4
6'''	1.00 d (6.5)	17.9

**Table 2.** UV data of the isolated rutin.

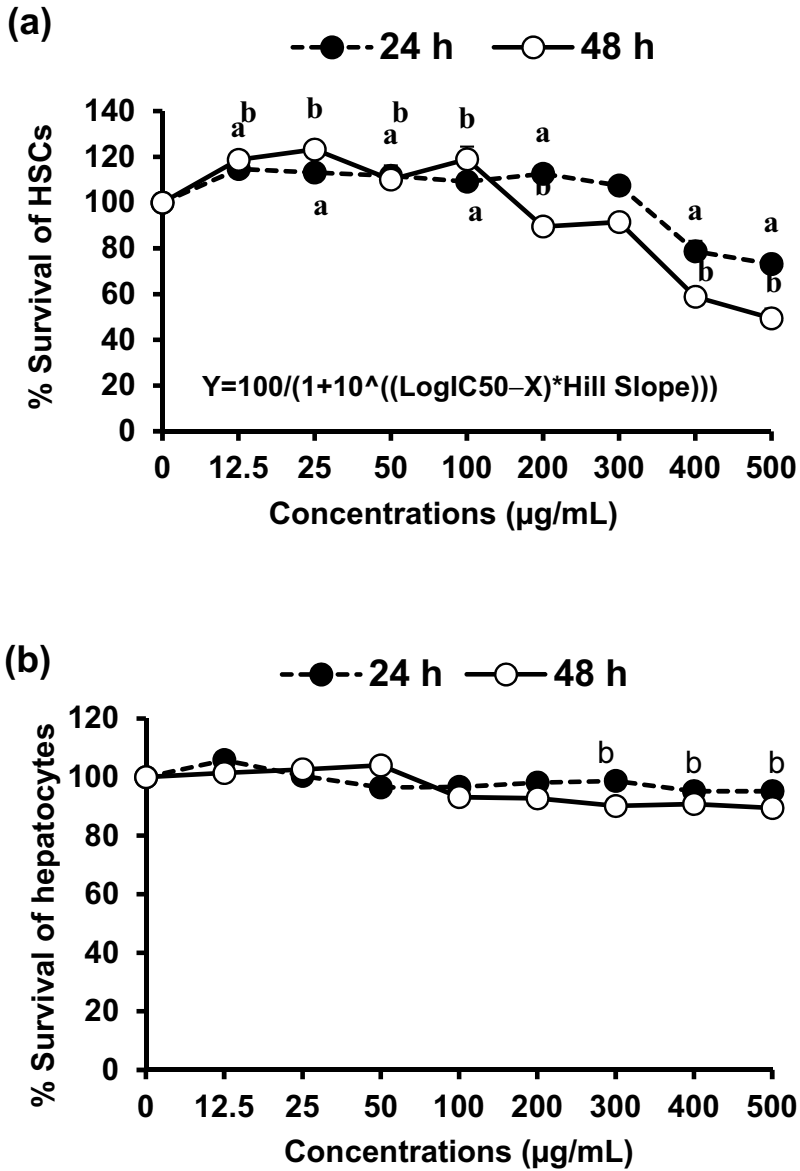
<b>MeOH</b>	257, 302sh, 359 ( <b>3-0-substituted flavonol</b> )
<b>NaOMe</b>	266, 328sh, 412 ( <b>free OH on ring A &amp; B</b> )
<b>AlCl<sub>3</sub></b>	272, 304sh, 420 ( <b>free OH on ring A &amp; B</b> )
<b>AlCl<sub>3</sub>/HCl</b>	266,298sh, 366, 402 ( <b>free OH at 5 &amp; ortho OH at ring B</b> )
<b>NaOAc.</b>	264, 300sh, 380 ( <b>free OH at 7 &amp; ortho OH at ring B</b> )
<b>NaOAc./H<sub>3</sub>BO<sub>3</sub></b>	260, 308sh, 377 ( <b>ortho OH at ring B</b> )



**Figure 1.** (a) Structure of the isolated and identified rutin. (b) HPLC analysis of the isolated rutin.

### ***Effect of Rutin on HSCs Proliferation and Hepatocytes Viability***

Treatment of cultured HSCs with rutin mitigated the HSCs proliferation in a concentration- and time-dependent manner, displaying a 50% inhibition concentration ( $IC_{50}$ ) of  $461 \mu\text{g}\cdot\text{mL}^{-1}$  at 48 h with 95% confidence interval (CI) of  $331.5\text{--}678.5 \mu\text{g}\cdot\text{mL}^{-1}$  (Fig. 2a). Rutin also showed no inhibitory effects on the viability of hepatocytes at 24- and 48-h. The viability of cells reached approximately 89.56% at the highest concentration ( $500 \mu\text{g}\cdot\text{mL}^{-1}$ ) and prolonged exposure (48 h) (Fig. 2b).



**Figure 2.** Effect of various concentrations of rutin on HSCs proliferation and hepatocytes viability. Data are presented as the mean ± SEM (n = 4) of absorbance of three different experiments. <sup>a</sup>P < .05 significantly different from corresponding untreated cells at 24 h, <sup>b</sup>P < .05 significantly different from corresponding untreated cells at 48 h (one-way ANOVA followed by Dunnett’s multiple comparison test). HSCs, hepatic stellate cells.

**Effect of Rutin on HSCs Activation and Apoptosis**

The image analysis of untreated activated HSCs showed enhanced α-SMA expression, as illustrated by the increase in the number of α-SMA positively stained cells. However, the exposure of activated HSCs to the IC<sub>50</sub>

concentrations of rutin attenuated the HSCs activation, as advocated by the pronounced reduction in  $\alpha$ -SMA expression when compared to untreated cells (Fig. 3a). The effect of rutin on HSCs apoptosis was also assessed using caspase-3 expression. Untreated activated cells showed few positively caspase-3 stained cells, meanwhile, incubation of HSCs with rutin resulted in a prominent elevation in caspase-3 expression by tenfold denoting a triggered apoptotic effect of rutin on activated HSCs (Fig. 3a). Treatment of cultured HSCs with rutin concentrations corresponding to approximately  $\frac{1}{4}$  (125  $\mu\text{g}\cdot\text{mL}^{-1}$ ),  $\frac{1}{2}$  (250  $\mu\text{g}\cdot\text{mL}^{-1}$ ), and onefold (500  $\mu\text{g}\cdot\text{mL}^{-1}$ ) the  $\text{IC}_{50}$  obtained after 48 h exhibited a decrease in TGF- $\beta$ 1 levels at a concentration of 500  $\mu\text{g}\cdot\text{mL}^{-1}$  by 19.65% as compared to untreated activated HSCs (Fig. 3b).

### **Effect of Rutin on Serum Liver Functions**

Compared to TAA-intoxicated untreated group, treatment of TAA-intoxicated rats with silymarin ameliorated the ALT levels by 29.54% whereas treatment with rutin restored the normal ALT levels. Besides, both silymarin and rutin reversed the elevated AST levels back to the normal (Fig. 4a).

### **Effect of Rutin on Liver GSH and MDA**

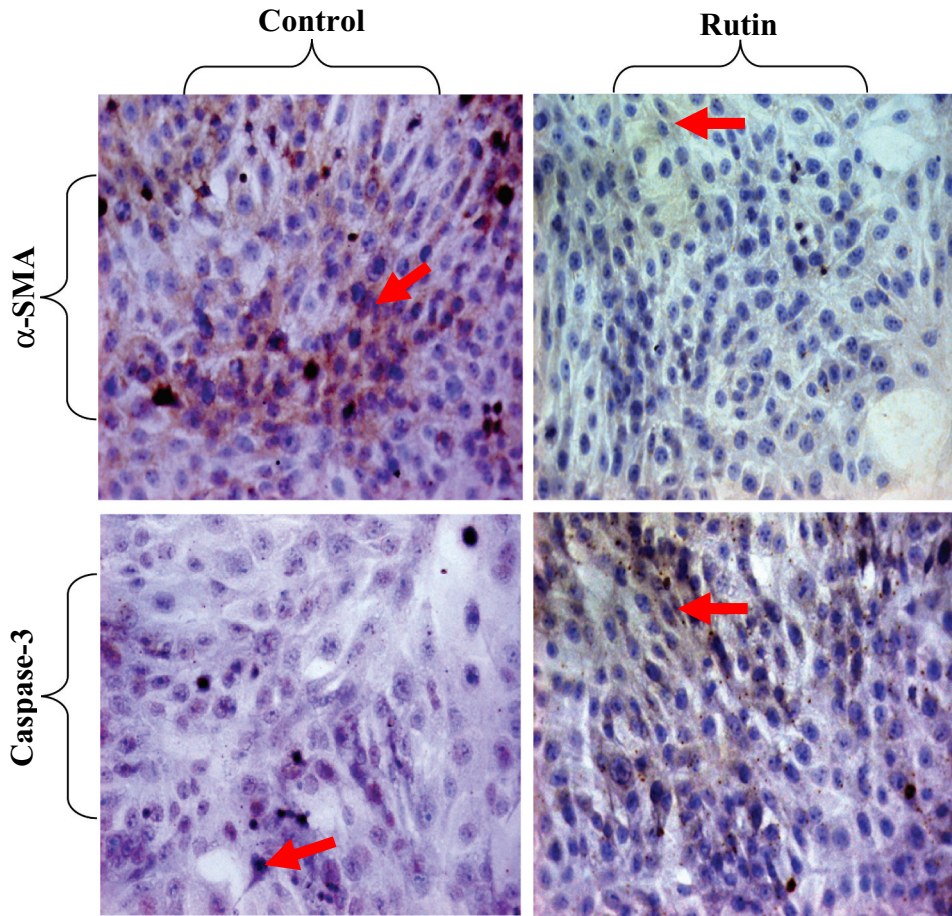
Treatment with silymarin induced almost twofold increments ( $P < .05$ ) in the liver GSH content accompanied with a significant decline in liver MDA levels by 36.05% when compared to TAA-intoxicated group. Meanwhile, rutin normalized the liver GSH content and induced a significant reduction ( $P < .05$ ) in liver MDA levels by 28.25%, together with a significant elevation in GSH content when compared to silymarin (Fig. 4b, c).

### **Effect of Rutin on Liver Fibrosis Markers**

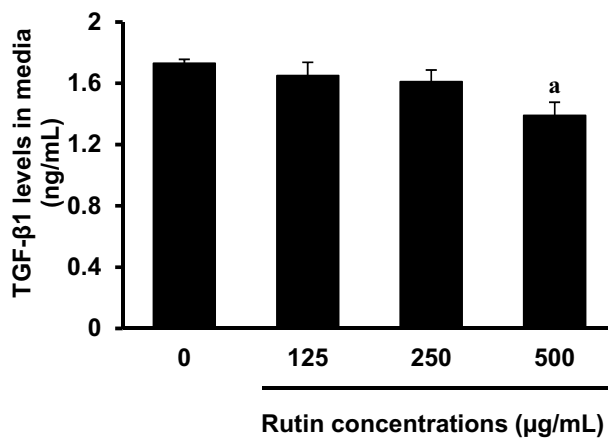
Administration of silymarin caused a significant reduction ( $P < .05$ ) in hepatic PDGF-BB, TGF- $\beta$ 1, TIMP-1 and HP levels by 29.6%, 37.28%, 14.76% and 47.42%, respectively, as compared to their corresponding TAA-intoxicated groups. Administration of rutin significantly ( $P < .05$ ) mitigated the hepatic levels of PDGF-BB, TGF- $\beta$ 1, TIMP-1 and HP by 27.78%, 32.38%, 23.25% and 47.22%, respectively, as compared to TAA-intoxicated group (Fig. 5).

### **Effect of Rutin on Liver Fibrosis Grade and Histopathology**

The effect of rutin on liver fibrosis grade and histopathological changes is shown in Fig. 6. Normal liver sections showed a preserved hepatic architecture with distinct hepatic cells, sinusoidal spaces and a central vein (Fig. 6a, b). On the other hand, liver sections of the TAA-intoxicated rats revealed disrupted



a



b

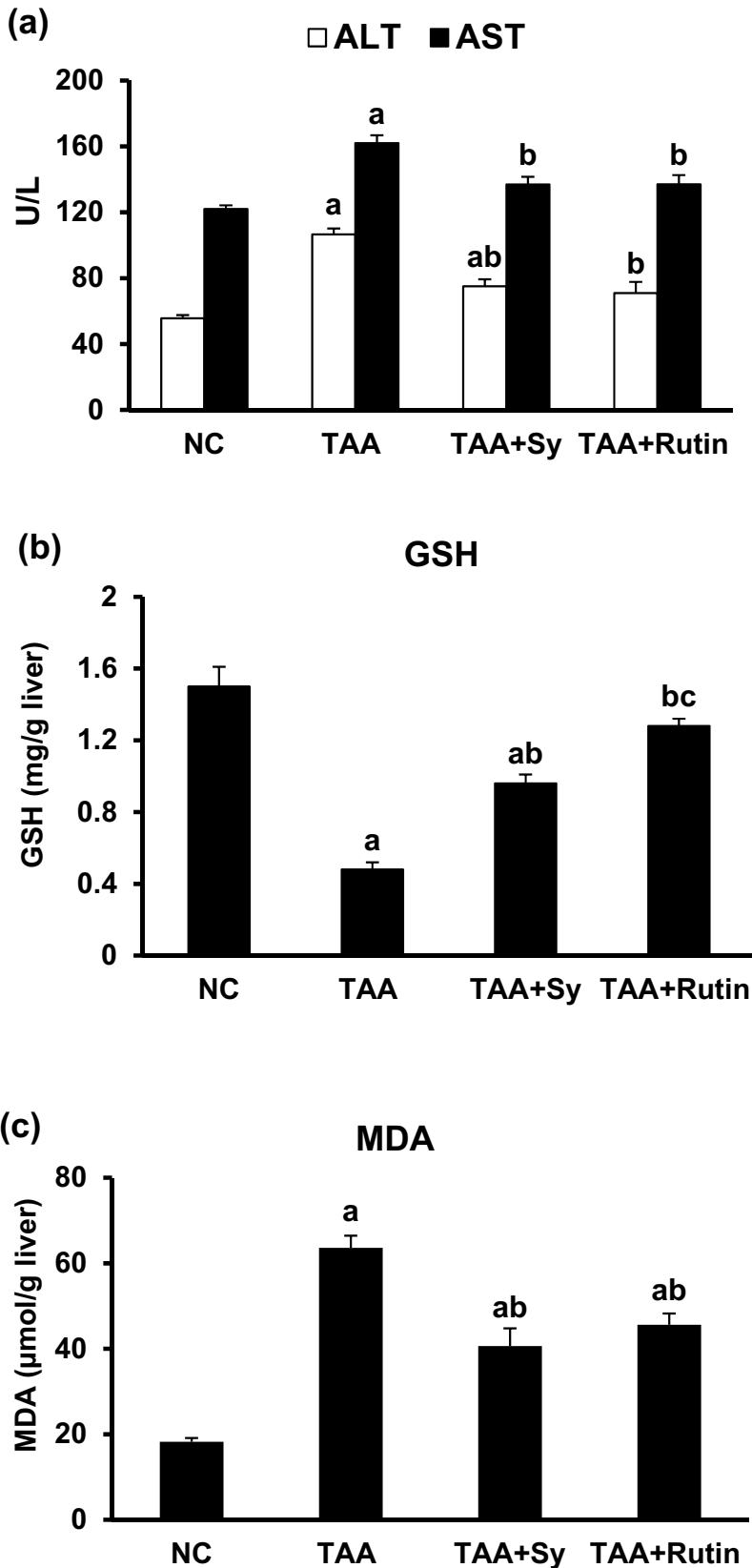
**Figure 3.** (a) Photomicrographs showing the effect of IC<sub>50</sub> concentrations of rutin on α-SMA and caspase-3 immunoreactivity in activated HSCs versus untreated cells (x 400). The expressions of α-

SMA and caspase-3 were estimated as the number of positively stained cells (red arrows).  $\alpha$ -SMA: alpha-smooth muscle actin. (b) Effect of  $\frac{1}{4}$ ,  $\frac{1}{2}$  and one-fold  $IC_{50}$  concentrations of rutin on TGF- $\beta$ 1 concentrations in cultured HSCs' media. Data are represented as mean  $\pm$  SEM (n = 3). <sup>a</sup> $P$  < .05 significantly different from corresponding untreated cells (one-way ANOVA followed by Tukey's multiple comparisons test). TGF- $\beta$ 1: transforming growth factor- $\beta$ 1.

architecture with extensive damage, characterized by centrilobular necrosis and deposition of collagen bundles surrounding the lobules mainly in the periportal regions that appeared as large fibrous septa forming regenerating micro and macronodules (Fig. 6a, b) showing an elevated fibrosis score of almost stage 4 (S4; Figure 6c). Administration of silymarin recovered the damaged hepatic tissues to some extent, as denoted by reduced levels of necrosis, mild thin and moderate fibrous collagen bands (Fig. 6a, b) as well as mitigated fibrosis scores of approximately S2 ( $1.83 \pm 0.31$  vs  $3.67 \pm 0.21$  for TAA group; Figure 6c). Notably, better liver recovery was observed in rats administered rutin where hepatic sections preserved their intact architecture with almost normal hepatocytes and reduced fibrosis scores to S1 ( $1.00 \pm 0.37$  vs  $3.67 \pm 0.21$  for TAA group; Figure 6c).

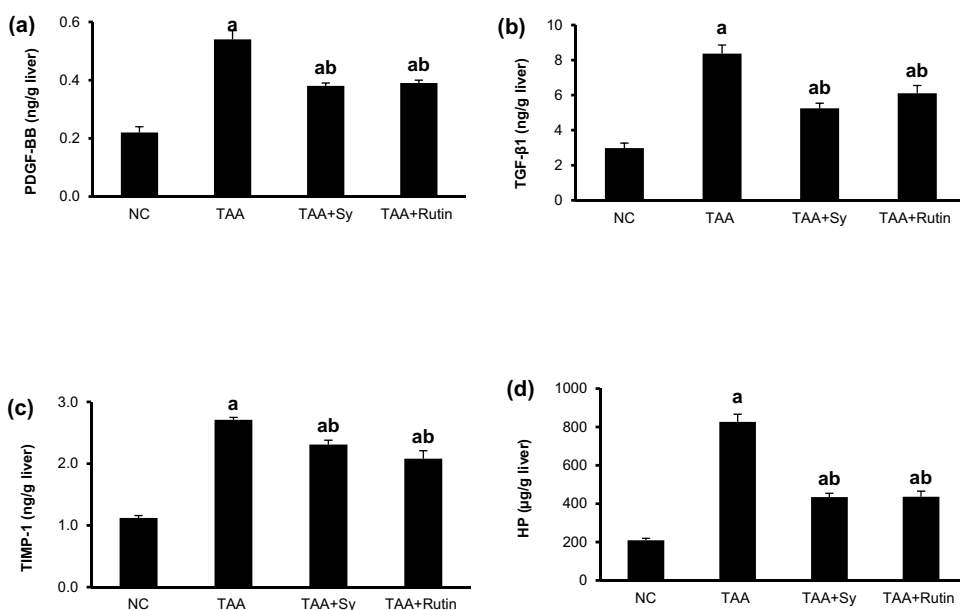
#### ***Effect of Rutin on HSCs Activation, Apoptosis and Hepatocytes Proliferation***

Normal liver expressed  $\alpha$ -SMA, a marker of activation, only in the hepatic vascular smooth muscle cells of the blood vessels (Fig. 7). However, TAA-intoxicated hepatic tissues showed a considerable elevation in  $\alpha$ -SMA protein expression as distinguished in areas of centrilobular and periportal fibrotic bands. Treatment with silymarin and rutin, respectively, notably modulated the  $\alpha$ -SMA protein expression. Moreover, the number of caspase-3 positive cells (apoptotic cells) detected in the normal control group was extremely low and was significantly elevated in the TAA-intoxicated liver sections. Silymarin and rutin depicted an increase in caspase-3 positive cells, respectively, as compared to TAA-intoxicated hepatic sections. However, rutin showed better enhancement in apoptosis when compared to silymarin treated group (Fig. 7). Caspase-3 positively stained cells were portrayed in portal and periportal areas, areas of activated HSCs, where collagen deposition is observed, rather than in parenchymal cells (hepatocytes). Additionally, PCNA, a proliferation marker for different cell types including hepatocytes, was expressed at basal low levels in hepatocytes of normal control. Conversely, its expression was upregulated in hepatocytes of TAA-intoxicated rats, which indicated a pronounced proliferation in attempt to repair the damaged liver tissues. Administration of silymarin distinctly diminished the proliferation of injured hepatocyte as depicted by few PCNA-stained cells, while the administration of rutin efficiently halted the proliferation of impaired hepatocytes (Fig. 7).



**Figure 4.** Effect of rutin on serum ALT and AST (a) levels as well as hepatic GSH (b) and MDA (c) levels. Data are represented as mean  $\pm$  SEM (n = 8). <sup>a</sup>P < .05 significantly different from normal

control, <sup>b</sup>*P* < .05 significantly different from TAA (one-way ANOVA followed by Tukey's multiple comparisons test). ALT: alanine aminotransferase, AST: aspartate aminotransferase, GSH: reduced glutathione, MDA: malondialdehyde, NC: normal control, TAA: thioacetamide, Sy: silymarin.

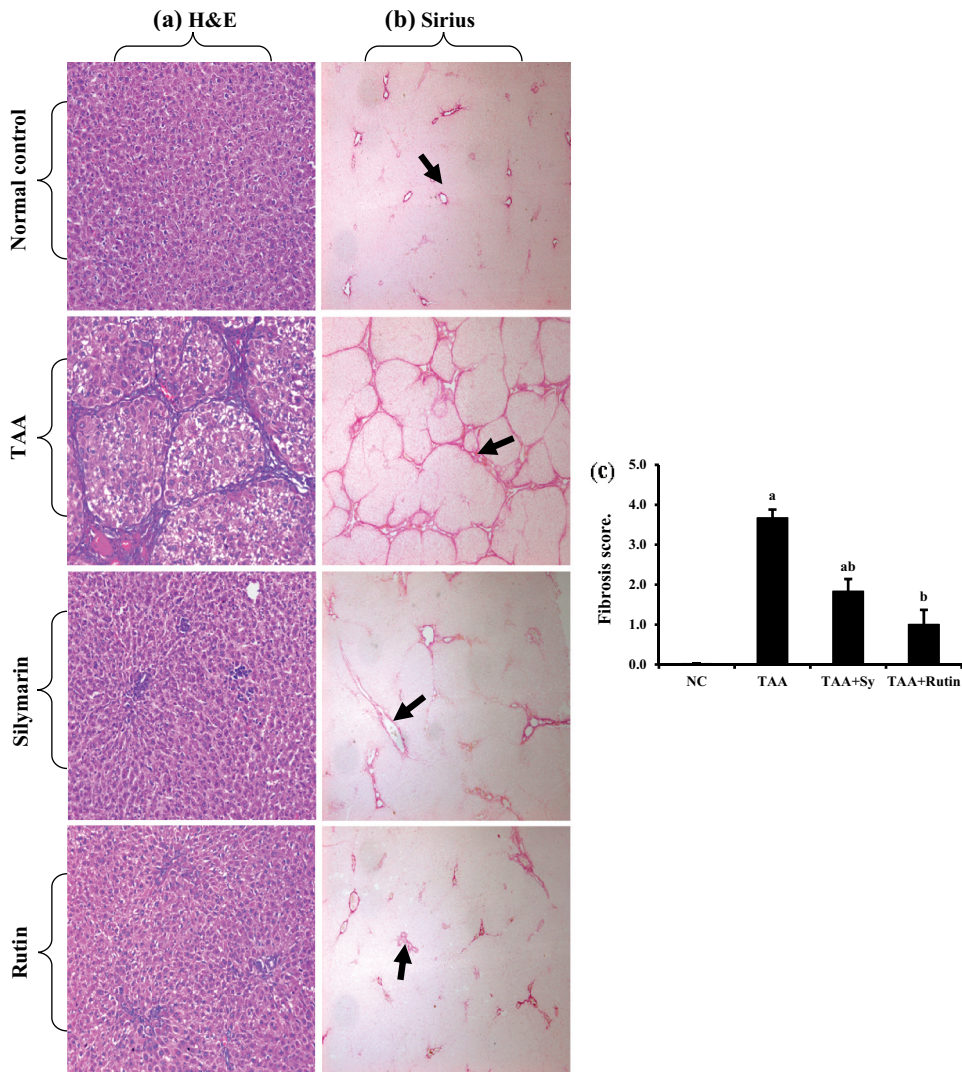


**Figure 5.** Effect of rutin on hepatic levels of PDGF-BB (a), TGF-β1 (b), TIMP-1 (c) and HP (d). Data are represented as mean ± SEM (n = 8). <sup>a</sup>*P* < .05 significantly different from normal control, <sup>b</sup>*P* < .05 significantly different from TAA, <sup>c</sup>*P* < .05 significantly different from silymarin (one-way ANOVA followed by Tukey's multiple comparisons test). PDGF-BB: platelet-derived growth factor-BB, TGF-β1: transforming growth factor- β1, TIMP-1: tissue inhibitor of metalloproteinases Type-1, HP: hydroxyproline, NC: normal control, TAA: thioacetamide, Sy: silymarin.

## Discussion

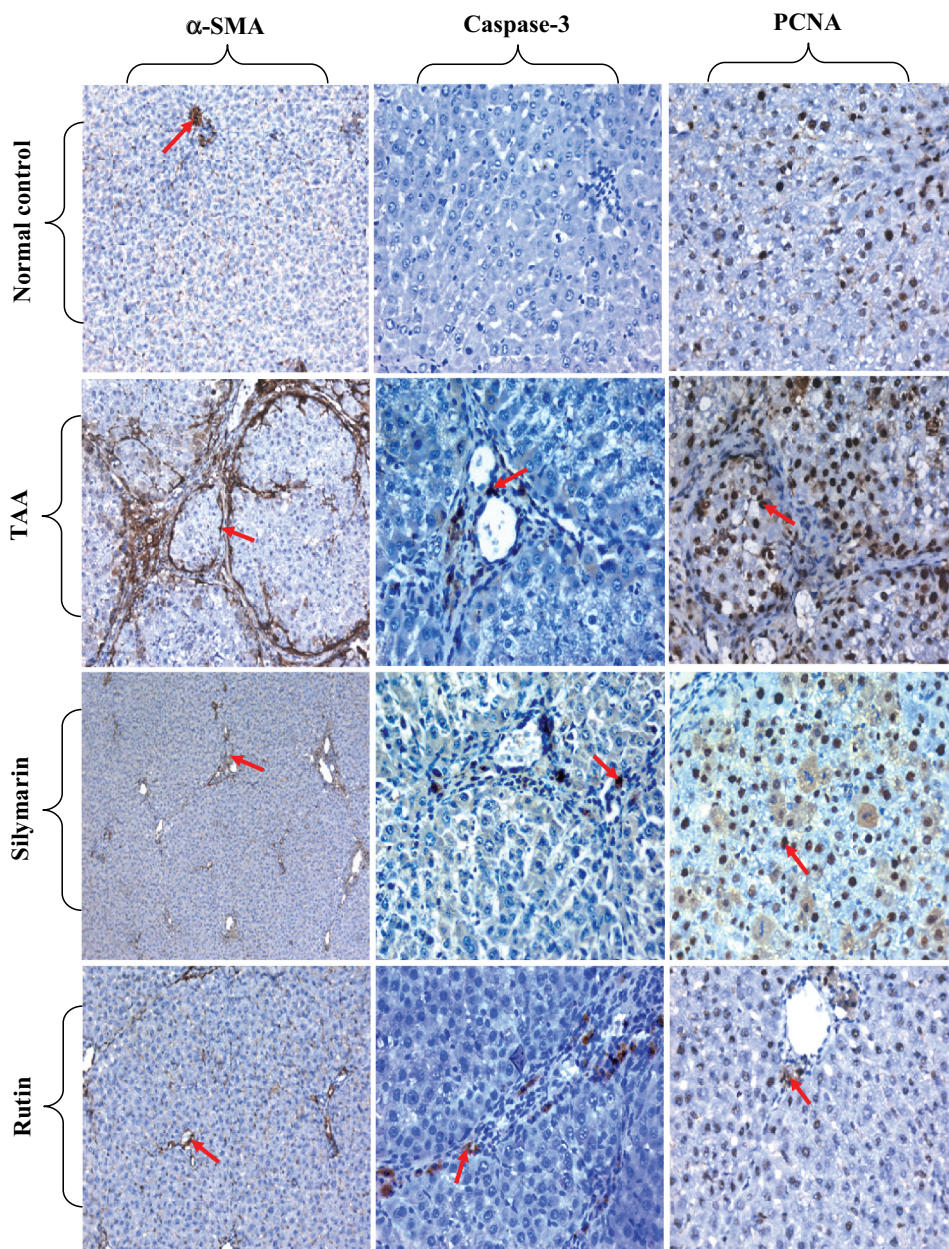
In the last decade, epidemiological and experimental studies revealed a positive correlation between the consumption of diet rich in fruits and vegetables and the reduced risk of certain chronic diseases.<sup>[24]</sup> Although there have been studies directed toward the evaluation of their hepatoprotective potential, yet their true value in prevention of liver diseases and/or their exact mechanisms of actions remains largely unknown.<sup>[25]</sup> This study attempted to provide insights on the antifibrotic efficacy of rutin by focusing mainly on their impact on HSCs *in vitro* and on TAA-induced liver fibrosis.

In the present study, treatment of cultured HSCs with rutin, for 48 h illustrated a significant time- and concentration-dependent decline in the proliferation of HSCs, displaying an IC<sub>50</sub> of 461 μg.mL<sup>-1</sup>. This finding confirms previous studies, which documented the antiproliferative activities of flavonoids, other than rutin, on HSC-T6 cell line.<sup>[12,13]</sup> Such observed



**Figure 6.** Effect of rutin on liver histopathology and hepatic collagen deposition. (a) Histopathological examinations of hepatic sections stained with H&E ( $\times 200$ ), (b) picro-sirius red stain ( $\times 50$ ) where the distribution of collagen fibers (black arrows) was visualized using imaging analysis software. (c) Numerical scoring of fibrosis stages. Fibrosis was graded into four stages: (S0) no fibrosis, (S1) expansion of fibrosis in portal area, (S2) peripheral fibrosis in portal area with retention of intralobular architecture, (S3) fibrous septum accompanied by intralobular structural disorders and (S4) early hepatic cirrhosis. Black arrows = strands of fibrosis. Data are expressed as mean ( $n = 6$ )  $\pm$  SEM; <sup>a</sup> $P < .05$  significantly different from normal control, <sup>b</sup> $P < .05$  significantly different from TAA (differences in fibrosis stages were evaluated using Kruskal-Wallis followed by Dunn's multiple comparisons test). TAA: thioacetamide.

suppression in HSCs proliferation could be explained in the light of the formerly reported *in vitro* antioxidant and pro-oxidant behaviors of polyphenolic compounds, particularly flavonoids where it selectively induced



**Figure 7.** Photomicrographs of immunohistochemically stained hepatic sections for  $\alpha$ -SMA (x 200), caspase-3 (x 400) and PCNA (x 400). The expression of  $\alpha$ -SMA, caspase-3 and PCNA were estimated as percentage of positively stained cells (red arrows point to the brown positively stained cells).  $\alpha$ -SMA: alpha-smooth muscle actin, PCNA: proliferating cellular nuclear antigen, TAA: thioacetamide.

oxidative damage and cytotoxic effects on HSCs through maneuvering their anti- and pro-oxidative capacities in hepatic malfunctions, thus promoting cell death and inactivation of activated HSCs .<sup>[26]</sup>

Results of this study revealed that also rutin triggered HSCs apoptosis; this could be attributed, at least in part, to its pro-oxidant effects. Moreover, rutin revealed its safety on primary isolated hepatocytes that exceeded 85% even after the highest concentrations (up to 500  $\mu\text{g}\cdot\text{mL}^{-1}$ ) and prolonged exposure (up to 48 h). These data add further support to previous study, which showed that polyphenolics selectively induce oxidative damage and cytotoxic effects on activated HSCs without showing any signs of cytotoxicity on hepatocytes.<sup>[26]</sup>

In the present investigation, histopathological examinations of chronic TAA intoxication for 12 weeks showed a disrupted architecture with extensive damage that appeared in the form of micro and macronodules. This was illustrated by an elevated fibrosis score (S4), which is a typical of TAA-induced liver fibrosis, and was evidenced by extensive increase in serum ALT and AST levels. In this study, rutin ameliorated the elevated serum levels of ALT and AST, denoting the property of rutin in maintaining the integrity of the cell membrane of liver cells, thereby protecting the liver from the adverse toxic effects of TAA. In addition, TAA-intoxicated rats exhibited a significant depletion in GSH stores accompanied by an increase in MDA hepatic levels. These results are in agreement with Shirin et al.,<sup>[19]</sup> which indicated that TAA metabolism resulted in an extensive production of ROS that exceeded the capacity of endogenous antioxidant protective GSH to eliminate them, and hence leading to GSH depletion. ROS also triggered the oxidation of polyunsaturated fatty acids, thereby resulting in an increase in MDA production.<sup>[27]</sup> Rutin replenished the hepatic GSH stores along with a significant decline in hepatic MDA levels through the down-regulation of ROS as formerly reported in  $\text{CCl}_4$ -induced liver injury thus accelerating the repair mechanism of the damaged cell membrane.<sup>[28]</sup>

Moreover, the free radicals resulting from TAA metabolism precede the activation of HSCs, which in turn secrete fibrinogen and growth factors leading to the progression of acute liver injury toward liver fibrosis. Among the growth factors, TGF- $\beta$ 1 and PDGF-BB are considered the most potent profibrogenic cytokines in liver fibrogenesis.<sup>[29]</sup> In the current study, rutin alleviated the up-regulated hepatic levels of TGF- $\beta$ 1 and PDGF-BB as well as  $\alpha$ -SMA expression. Such outcomes could be explained and further strengthened with those obtained *in vitro* where rutin reduced the TGF- $\beta$ 1 concentrations in culture media in a concentration-dependent manner as well as the number of activated HSCs, as represented herein by the diminution in  $\alpha$ -SMA expression.

Additionally, activated HSCs act as the main source of excessive production and deposition of ECM, where activated HSCs synthesize TIMPs that cause further increase in collagen deposition mainly collagen type I.<sup>[30]</sup> In the present study, TAA intoxication caused a dramatic increase in the hepatic levels of TIMP-1 and HP (a major component of collagen), thus reflecting an

increase for deposited collagen, which substantiates a previous study by Kadir et al.<sup>[20]</sup> Results reported in this study were confirmed by the histological examination, using sirius red stain, of TAA-intoxicated liver tissues, which supported the presence of fibrosis (S4), numerous fiber extension and collagen deposition around the hepatic lobules. A similar increase in collagen I and TIMPs expression had been observed in other toxins-induced liver fibrosis in rats.<sup>[31]</sup> Herein, besides the down-regulation of HSCs activation, rutin reduced the fibrosis scores and TAA-induced collagen deposition and hence could help in the prevention of the progression of liver fibrosis. These results were comparable with a previous study, which showed that administration of rutin markedly reduced TIMP-1 expression and correspondingly increased collagen lysis.<sup>[32]</sup>

Furthermore, a small number of apoptotic cells were observed in TAA-intoxicated liver tissues, as illustrated by few caspase-3 positively stained cells, which is in harmony with the study of Kadir et al.<sup>[20]</sup> This could be attributed to the centrilobular necrosis caused by TAA biotransformation, where the toxicity induced by TAA favored necrosis over apoptosis.<sup>[33]</sup> Herein, rutin did not only inhibit the activation or proliferation of HSCs but also triggered the apoptosis of these cells in animals' hepatic tissues as indicated by increased caspase-3 expression in comparison to TAA-intoxicated rats. Such enhanced apoptosis might be related to the suppressed TIMP-1 levels and deposited collagen, recorded herein. These data confirm and extend the circumstantial evidence from earlier studies, which documented that during recovery of liver fibrosis, the apoptosis of activated HSCs led to reduction in both hepatic collagen production and TIMPs over expression, thereby resulting in collagen lysis and the up-regulation of caspases.<sup>[34]</sup>

Adding on, the proliferative activity of hepatocytes was examined via PCNA staining. Hepatocytes of TAA-intoxicated rats showed more PCNA-positively stained cells, indicating severe damage and increased number of necrotic cells; this finding is in agreement with a former study,<sup>[35]</sup> which reported that PCNA was elevated in hepatocytes of rats injected with TAA. In this study, rutin inhibited the proliferation of damaged hepatocytes as indicated by significant reduction in PCNA staining when compared to the higher damage and the up-regulated PCNA expressed levels in the TAA-intoxicated rats. This finding supported the idea that rutin did not only regulate HSCs activation but also the cell cycle progression of hepatocytes thus playing a positive role in liver regeneration.

## Conclusions

In this work, the hepatoprotective and antifibrotic efficacy of rutin was compared to that of silymarin, and rutin exhibited some superior effects over silymarin as illustrated by; restoration of the normal ALT levels and GSH

stores, reduction of fibrosis score, enhancement of apoptosis as well as inhibiting the proliferation of impaired hepatocytes. In view of the obtained results, it could be concluded that rutin could be a promising candidate in treating hepatic fibrosis. This could be attributed to rutin ability to inhibit the proliferation and activation of HSCs together with increasing their apoptotic tendency. Such obtained effects would urge further studies on the capability of rutin to combat liver fibrosis.

## Acknowledgments

The authors would like to express their deepest appreciation and gratitude to Prof. S.L. Friedman, Mount Sinai School of Medicine, NY, for his generous gift of HSC-T6 cells.

## Disclosure Statement

All authors declare that there is no conflict of interest.

## Funding

This work was a part of project and supported by the [Theodor Bilharz Research Institute] under Grant [ID-MS-99/A (PI: Naglaa El-Lakkany)].

## ORCID

S. H. Seif el-Din  <http://orcid.org/0000-0002-0357-3467>

N. M. El-Lakkany  <http://orcid.org/0000-0002-5783-9945>

## References

- [1] Friedman, S. L.; Hepatic Fibrosis: emerging Therapies. *Dig Dis.* 2015, 33, 504–507. DOI: 10.1159/000374098.
- [2] Lee, Y. A.; Wallace, M. C.; Friedman, S. L. Pathobiology of Liver Fibrosis: a Translational Success Story. *Gut.* 2015, 64(5), 830–841. DOI: 10.1136/gutjnl-2014-306842.
- [3] Yin, C.; Evason, K. J.; Asahina, K.; Stainier, D. Y. Hepatic Stellate Cells in Liver Development, Regeneration, and Cancer. *J. Clin. Invest.* 2013, 123, 1902–1910. DOI: 10.1172/JCI66369.
- [4] Iredale, J.; Benyon, R.; Pickering, J.; McCullen, M.; Northrop, M.; Pawley, S.; Hovell, C.; Arthur, M. J. Mechanisms of Spontaneous Resolution of Rat Liver Fibrosis. Hepatic Stellate Cell Apoptosis and Reduced Hepatic Expression of Metalloproteinase Inhibitors. *J. Clin. Invest.* 1998, 102, 538–549. DOI: 10.1172/JCI1018.
- [5] Krizhanovsky, V.; Yon, M.; Dickins, R. A.; Hearn, S.; Simon, J.; Miething, C.; Yee, H.; Zender, L.; Lowe, S. W. Senescence of Activated Stellate Cells Limits Liver Fibrosis. *Cell.* 2008, 134, 657–667. DOI: 10.1016/j.cell.2008.06.049.
- [6] Kisseleva, T.; Cong, M.; Paik, Y.; Scholten, D.; Jiang, C.; Benner, C.; Iwaisako, K.; Moore-Morris, T.; Scott, B.; Tsukamoto, H.; et al. Myofibroblasts Revert to an Inactive

- Phenotype during Regression of Liver Fibrosis. *Proc. Natl. Acad. Sci.* **2012**, *109*, 9448–9453. DOI: [10.1073/pnas.1201840109](https://doi.org/10.1073/pnas.1201840109).
- [7] Duval, F.; Moreno-Cuevas, J. E.; González-Garza, M. T.; Maldonado-Bernal, C.; Cruz-Vega, D. E. Liver Fibrosis and Mechanisms of the Protective Action of Medicinal Plants Targeting Inflammation and the Immune Response. *Int. J. Inflamm.* **2015**, *2015*, 943497. DOI: [10.1155/2015/943497](https://doi.org/10.1155/2015/943497).
- [8] Spencer, J. P.; Abd El Mohsen, M. M.; Minihane, A. M.; Mathers, J. C. Biomarkers of the Intake of Dietary Polyphenols: strengths, Limitations and Application in Nutrition Research. *Br. J. Nutr.* **2008**, *99*, 12–22. DOI: [10.1017/S0007114507798938](https://doi.org/10.1017/S0007114507798938).
- [9] Ou, T. T.; Hsu, M. J.; Chan, K. C.; Huang, C. N.; Ho, H. H.; Wang, C. J. Mulberry Extract Inhibits Oleic Acid-induced Lipid Accumulation via Reduction of Lipogenesis and Promotion of Hepatic Lipid Clearance. *J. Sci. Food Agric.* **2011**, *91*, 2740–2748. DOI: [10.1002/jsfa.4489](https://doi.org/10.1002/jsfa.4489).
- [10] Liu, Q.; Pan, R.; Ding, L.; Zhang, F.; Hu, L.; Ding, B.; Zhu, L.; Xia, Y.; Dou, X. Rutin Exhibits Hepatoprotective Effects in a Mouse Model of Non-alcoholic Fatty Liver Disease by Reducing Hepatic Lipid Levels and Mitigating Lipid-induced Oxidative Injuries. *Int. Immunopharmacol.* **2017**, *49*, 132–141. DOI: [10.1016/j.intimp.2017.05.026](https://doi.org/10.1016/j.intimp.2017.05.026).
- [11] Shenbagam, M.; Nalini, N. Dose Response Effect of Rutin a Dietary Antioxidant on Alcohol-induced Prooxidant and Antioxidant Imbalance - a Histopathologic Study. *Clin Pharmacol.* **2011**, *25*, 493–502. DOI: [10.1111/j.1472-8206.2010.00861.x](https://doi.org/10.1111/j.1472-8206.2010.00861.x).
- [12] Zhang, M.; Zhang, J. P.; Ji, H. T.; Wang, J. S.; Qian, D. H. Effect of Six Flavonoids on Proliferation of Hepatic Stellate Cells *in Vitro*. *Acta Pharmacol Sin.* **2000**, *21*, 253–256.
- [13] Qi, L. H.; Kang, L. P.; Zhang, J. P.; Shi, N.; Zhang, M.; Wu, T. M. Antifibrotic Effects of Genistein and Quercetin. *in vitro Yao Xue Xue Bao.* **2001**, *36*, 648–651.
- [14] Xie, Y.; Wang, G.; Wang, H.; Yao, X.; Jiang, S.; Kang, A.; Zhou, F.; Xie, T.; Hao, H. Cytochrome P450 Dysregulations in Thioacetamide-induced Liver Cirrhosis in Rats and the Counteracting Effects of Hepatoprotective Agents. *Drug Metab. Dispos.* **2012**, *40*, 796–802. DOI: [10.1124/dmd.111.043539](https://doi.org/10.1124/dmd.111.043539).
- [15] Chen, I. S.; Chen, Y. C.; Chou, C. H.; Chuang, R. F.; Sheen, L. Y.; Chiu, C. H. Hepatoprotection of Silymarin against Thioacetamide-induced Chronic Liver Fibrosis. *J. Sci. Food Agric.* **2012**, *92*, 1441–1447. DOI: [10.1002/jsfa.4723](https://doi.org/10.1002/jsfa.4723).
- [16] Ledda-Collumbano, G. M.; Coni, P.; Curto, M.; Giacomini, L.; Faa, G.; Oliverio, S.; Piacentini, M.; Columbano, A. Induction of Two Different Modes of Cell Death, Apoptosis and Necrosis, in Rat Liver after a Single Dose of Thioacetamide. *Am. J. Pathol.* **1991**, *139*, 1099–1109.
- [17] El-Maadawy, W. H.; Hammam, O. A.; Seif El-Din, S. H.; El-Lakkany, N. M.  $\alpha$ -Lipoic Acid Modulates Liver Fibrosis: a Cross Talk between TGF- $\beta$ 1, Autophagy, and Apoptosis. *Hum. Exp. Toxicol.* **2020**, *39*(4), 440–450. DOI: [10.1177/0960327119891212](https://doi.org/10.1177/0960327119891212).
- [18] Seglen, P. O.; Preparation of Isolated Rat Liver Cells. *Methods Cell Biol.* **1976**, *13*, 29–83.
- [19] Shirin, H.; Sharvit, E.; Aeed, H.; Gavish, D.; Bruck, R. Atorvastatin and Rosuvastatin Do Not Prevent Thioacetamide-induced Liver Cirrhosis in Rats. *World J. Gastroenterol.* **2013**, *19*, 241–248. DOI: [10.3748/wjg.v19.i2.241](https://doi.org/10.3748/wjg.v19.i2.241).
- [20] Kadir, F. A.; Kassim, N. M.; Abdulla, M. A.; Yehye, W. A. Hepatoprotective Role of Ethanolic Extract of *Vitex Negundo* in Thioacetamide-induced Liver Fibrosis in Male Rats. *Evid. Based Complement. Alternat. Med.* **2013**, *2013*, 739850. DOI: [10.1155/2013/739850](https://doi.org/10.1155/2013/739850).
- [21] Khan, R. A.; Khan, M. R.; Sahreen, S. CCl<sub>4</sub>-induced Hepatotoxicity: protective Effect of Rutin on P53, CYP2E1 and the Antioxidative Status in Rat. *BMC Complement. Altern. Med.* **2012**, *12*(1), 178. DOI: [10.1186/1472-6882-12-178](https://doi.org/10.1186/1472-6882-12-178).

- [22] Woessner, J. F., Jr.; The Determination of Hydroxyproline in Tissue and Protein Samples Containing Small Proportions of This Imino Acid. *Arch. Biochem. Biophys.* **1961**, *93*, 440–447. DOI: [10.1016/0003-9861\(61\)90291-0](https://doi.org/10.1016/0003-9861(61)90291-0).
- [23] Li, L.; Hu, Z.; Li, W.; Hu, M.; Ran, J.; Chen, P.; Sun, Q. Establishment of a Standardized Liver Fibrosis Model with Different Pathological Stages in Rats. *Gastroenterol Res Pract.* **2012**, *2012*, 560345. DOI: [10.1155/2012/560345](https://doi.org/10.1155/2012/560345).
- [24] Capanoglu, E.; De Vos, R. C. H.; Hall, R. D.; Boyacioglu, D.; Beekwilder, J. Changes in Polyphenol Content during Production of Grape Juice Concentrate. *Food Chem.* **2013**, *139*(1–4), 521–526. DOI: [10.1016/j.foodchem.2013.01.023](https://doi.org/10.1016/j.foodchem.2013.01.023).
- [25] Bhawna, S.; Kumar, S. U. Hepatoprotective Activity of Some Indigenous Plants. *Int J Pharm Tech Res.* **2009**, *4*, 1330–1334.
- [26] Galati, G.; Sabzevari, O.; Wilson, J. X.; O'Brien, P. J. Prooxidant Activity and Cellular Effects of the Phenoxyl Radicals of Dietary Flavonoids and Other Polyphenolics. *Toxicology.* **2002**, *177*, 91–104. DOI: [10.1016/S0300-483X\(02\)00198-1](https://doi.org/10.1016/S0300-483X(02)00198-1).
- [27] Okuyama, H.; Nakamura, H.; Shimahara, Y.; Araya, S.; Kawada, N.; Yamaoka, Y.; Yodoi, J. Overexpression of Thioredoxin Prevents Acute Hepatitis Caused by Thioacetamide or Lipopolysaccharide in Mice. *Hepatology.* **2003**, *37*, 1015–1025. DOI: [10.1053/jhep.2003.50203](https://doi.org/10.1053/jhep.2003.50203).
- [28] Yuan, L. P.; Chen, F. H.; Ling, L.; Bo, H.; Chen, Z. W.; Li, F.; Zhong, M. M.; Xia, L. J. Protective Effects of Total Flavonoids of *Bidens Bipinnata* L. Against Carbon Tetrachloride-induced Liver Fibrosis in Rats. *J. Pharm. Pharmacol.* **2008**, *60*, 1393–1402. DOI: [10.1211/jpp/60.10.0016](https://doi.org/10.1211/jpp/60.10.0016).
- [29] Zhou, J.; Zhong, D. W.; Wang, Q. W.; Miao, X. Y.; Xu, X. D. Paclitaxel Ameliorates Fibrosis in Hepatic Stellate Cells via Inhibition of TGF-beta/Smad Activity. *World J. Gastroenterol.* **2010**, *16*, 3330–3334. DOI: [10.3748/wjg.v16.i26.3330](https://doi.org/10.3748/wjg.v16.i26.3330).
- [30] Tsukada, S.; Parsons, C. J.; Rippe, R. A. Mechanisms of Liver Fibrosis. *Clin. Chim. Acta.* **2006**, *364*, 33–60.
- [31] Galli, A.; Svegliati-Baroni, G.; Ceni, E.; Milani, S.; Ridolfi, F.; Salzano, R.; Tarocchi, M.; Grappone, C.; Pellegrini, G.; Benedetti, A.; et al. Oxidative Stress Stimulates Proliferation and Invasiveness of Hepatic Stellate Cells via a MMP2-mediated Mechanism. *Hepatology.* **2005**, *41*(5), 1074–1084. DOI: [10.1002/hep.20683](https://doi.org/10.1002/hep.20683).
- [32] Hafez, M. M.; Al-Harbi, N. O.; Al-Hoshani, A. R.; Al-Hosaini, K. A.; Al Shrari, S. D.; Al Rejaie, S. S.; Sayed-Ahmed, M. M.; Al-Shabanah, O. A. Hepatoprotective Effect of Rutin via IL-6/STAT3 Pathway in CCl<sub>4</sub>-induced Hepatotoxicity in Rats. *Biol. Res.* **2015**, *48*, 3–10. DOI: [10.1186/s40659-015-0022-y](https://doi.org/10.1186/s40659-015-0022-y).
- [33] Sarkar, M. K.; Sil, P. C. Hepatocytes are Protected by Herb *Phyllanthus Niruri* Protein Isolate against Thioacetamide Toxicity. *Pathophysiology.* **2007**, *14*(2), 113–120. DOI: [10.1016/j.pathophys.2007.08.001](https://doi.org/10.1016/j.pathophys.2007.08.001).
- [34] Friedman, S. L.; Evolving Challenges in Hepatic Fibrosis. *Nat. Rev. Gastroenterol. Hepatol.* **2010**, *7*(8), 425–436. DOI: [10.1038/nrgastro.2010.97](https://doi.org/10.1038/nrgastro.2010.97).
- [35] Tousson, E.; Ali, E. M. M.; Moustafa, A. A.; Moselhey, S. S.; El-Said, K. S. Proliferating Cell Nuclear Antigen as a Biomarker for Thioacetamide-induced Hepatotoxicity of Rat Liver. *Am Zool Res.* **2014**, *2*, 51–54.