

See discussions, stats, and author profiles for this publication at: <https://www.researchgate.net/publication/321398168>

# In situ distribution of hepatitis C virus (HCV) RNA in the liver: Relationship to histopathology and serum HCV RNA levels

Article · January 2009

CITATIONS

0

READS

26

1 author:



Ahmed Aref

Modern Sciences and Arts University

21 PUBLICATIONS 269 CITATIONS

SEE PROFILE

Some of the authors of this publication are also working on these related projects:



In situ distribution of hepatitis C virus (HCV) RNA in the... [View project](#)



Bat-26 is Associated with Clinical Stage and Lymph Node Status in Schistosomiasis Associated Bladder Cancer [View project](#)

Full Length Research paper

# ***In situ* distribution of hepatitis C virus (HCV) RNA in the liver: Relationship to histopathology and serum HCV-RNA levels**

**Thanaa El-Sayed Helal<sup>1\*</sup>, Mahmoud Ismail Hassan<sup>2</sup>, Munir Ali<sup>3</sup> El-Ganzuri, Ahmed Mostafa Ahmed<sup>3</sup> and Sahar Ezzelarab<sup>4</sup>**

<sup>1</sup>Department of Pathology, Ain Shams University, Cairo, Egypt.

<sup>2</sup>Department of Biochemistry, Faculty of Medicine, Ain Shams University, Cairo, Egypt.

<sup>3</sup>Faculty of Dentistry, MSA University, Cairo, Egypt

<sup>4</sup>Early Cancer Detection Unit, Faculty of medicine Ain Shams University, Cairo, Egypt.

Accepted 12 February, 2009

***In situ* hybridization (ISH) technique was applied to 60 liver biopsies obtained from Egyptian patients with chronic HCV hepatitis in an attempt to: assess the tissue localization of HCV RNA in the liver and to investigate its relationship to the liver pathology, serum level of alanine transaminase (ALT) and viral load in the serum. No similar studies have been reported from Egypt, which is an area of high HCV prevalence. ISH labeling for HCV was observed in 24 of the 60 liver biopsies from HCV infected patients (40%) as compared to the complete negative ISH results in the 10 control liver biopsies from patients with non HCV hepatitis. ISH positivity was seen only in the liver cells and it was usually cytoplasmic. ISH results were not significantly related to the patients' age, sex, histologic features of HCV hepatitis, grade of disease activity, stage of fibrosis, serum ALT levels or serum HCV RNA. However, ISH was statistically correlated to the grade of liver cell dysplasia ( $r = 0.49$ ,  $P < 0.0001$ ). The latter was also significantly correlated to the level of HCV RNA in the serum as measured by branched DNA technique ( $r = 0.75$ ,  $P < 0.0001$ ). In conclusion, the present study suggests that the load of HCV RNA in the liver is not related to extent of liver injury, serum ALT levels or the viral load in the serum. More importantly, the significant correlation between the grade of dysplasia and both the tissue and serum load of the virus, leads to the assumption that HCV has a direct carcinogenic effect on liver cells.**

**Key words:** HCV RNA, *in situ* hybridization, liver pathology, dysplasia.

## **INTRODUCTION**

Liver biopsy is an essential investigatory tool in patients with chronic hepatitis C, since it is used to confirm the presence of hepatitis C virus (HCV) infection (Lok and Gunaratnam, 1997). It is also important in determining the degree of the inflammatory activity and the stage of fibrosis, which have been shown to correlate with the risk

of developing cirrhosis (Yano et al., 1996). The stage of fibrosis has also been regarded as the most important predictor of response to interferon therapy (Tuboto et al., 1994; Chemello et al., 1995; Tsubota et al., 1996).

Although detection of HCV-RNA in the serum using polymerase chain reaction (PCR) is the gold standard to confirm HCV infection (Weiner et al., 1990), direct demonstration of the virus in the liver tissue seems necessary because it gives more insight into the pathophysiology of the disease. This has been achieved by reverse transcription polymerase chain reaction (RT-PCR) (Fong et al., 1991; Chn et al., 1994; Sakanoto et al., 1994; De Moliner et al., 1998). Nevertheless, RT-PCR could not provide data about localization of HCV-RNA and its intracellular distribution in the liver tissue.

\*Corresponding author. E-mail: [thanaahelal@hotmail.com](mailto:thanaahelal@hotmail.com). Tel.: 202 0101542426. Fax: 202 6859928.

**Abbreviations:** HCV, hepatitis C virus; PCR, polymerase chain reaction; RT-PCR, reverse transcription PCR; ISH, *in situ* hybridization; ALT, alanine aminotransferase; HbsAg, hepatitis B surface antigen; HBcAb, hepatitis B core antibody.

Recently, many studies have reported the use of *in situ* hybridization (ISH) technique which has the advantage of direct visualization of HCV-RNA, while keeping tissue architecture (Negro et al., 1992; Lamas et al., 1992; Tanaka et al., 1993; Yamada et al., 1993; Haruna et al., 1993; Gastaldi et al., 1995; Kojima et al., 1996; Cho et al., 1996; Felgar et al., 1996; Angello et al., 1998; Gosalvez et al., 1998; Chang et al., 2000; de Lucas et al., 2001). However, these ISH studies have shown several conflicting issues.

First, the percentage of positive biopsies from infected patients is quite variable ranging from 40% (Lamas et al., 1992; Tanaka et al., 1993; Yamada et al., 1993) to 100% (Gosalvez et al., 1998; Chang et al., 2000). Second, the site of HCV-RNA in the liver is also a matter of controversy. Some investigators have demonstrated HCV-RNA in the hepatocytes only (Tanaka et al., 1993; Haruna et al., 1993; Kojima et al., 1996; Cho et al., 1996; Felgar et al., 1996; Angello et al., 1998; Gosalvez et al., 1998). Others have reported its presence not only in the hepatocytes but also in the mononuclear cells (Lamas et al., 1992; Tanaka et al., 1993; Yamada et al., 1993; Haruna et al., 1993; Gastaldi et al., 1995; Kojima et al., 1996; Cho et al., 1996; Felgar et al., 1996; Angello et al., 1998; Gosalvez et al., 1998; Chang et al., 2000) and bile duct epithelium (Gastaldi et al., 1995). Third, assessment of the relationship between the ISH results on one hand and liver histopathology, serum alanine aminotransferase (ALT), serum HCV-RNA measurement on the other hand, has yielded very confusing data. Moreover, most of the studies correlated ISH with only one parameter, that is, liver histology (Angello et al., 1998), ALT (Kojima et al., 1996; Cho et al., 1996), serum HCV-RNA (Gosalvez et al., 1998), or two of them (Haruna et al., 1993; Haruna et al., 1993; Rod-riguez-Ingo et al., 1999). The studies which investigated the relationship between ISH and all these factors simultaneously are very few (Morimoto et al., 1997).

In the present study, liver biopsies from Egyptian patients with chronic HCV hepatitis were analyzed by ISH technique for detection of HCV RNA and assessment of its distribution at the cellular and subcellular levels within the liver tissue. In addition, the hepatic viral load has been correlated to histopathologic changes, serum ALT levels and viral load in the serum. To the best of our knowledge, no similar documented studies have been reported from Egypt, which is an area of high HCV prevalence (Abdel-Wahab et al., 1994; Arthur et al., 1997; Abdel et al., 2000).

## MATERIALS AND METHODS

### Patients

The current study included 60 patients (32 females and 28 males with aged ranged between 20 and 65 years and mean age 44.7

years), with chronic liver disease due to HCV infection. The latter was confirmed by estimation measurement of serum HCV antibodies using enzyme linked immunoassay according to Kuo et al. (1989) as well as detection of HCV-RNA in the serum performed by reverse transcriptase polymerase chain reaction (RT-PCR) as described by Castillo et al. (1992). HCV RNA template was prepared by taking 3  $\mu$ l of patient's serum to which 7  $\mu$ l of PBS was added. This mixture was heated at 95°C for 3 min for denaturation of the sample. In positive cases, quantitation of serum HCV-RNA was achieved by using branched DNA technology designed by Chiron Diagnostics (NJ, USA). HBsAg and HbCAb were determined by enzyme immunoassay to make sure that HCV infected patients included in the study had no associated hepatitis B virus infection. Liver function was assessed by estimation of serum alanine aminotransferase (ALT) levels. The cut off value was 25 U/L. Ten patients negative for HCV antibodies and HCV-RNA in the serum were selected as negative control. Three subjects were positive for HBsAg and HbCAb, 5 had schistosomal hepatic fibrosis and 2 had autoimmune hepatitis.

### Histopathology

Liver tissue was obtained from all patients by needle biopsy under informed consent and before starting any type of therapy. The tissue specimens were fixed in 10% buffered formalin and embedded in paraffin. Standard hematoxylin and eosin (H and E) and Masson trichrome-stained sections were prepared and examined histologically for:

- i.) The characteristic histopathologic features of HCV infection which included bile duct damage, portal lymphoid aggregates, steatosis and lymphocytic infiltrate of the hepatic lobules (Scheuer et al., 1992; Gerber, 1994; Scheuer et al., 1997).
- ii.) The grade of disease activity and stage of fibrosis according to Scheuer (1991) and Tsui (1996). Grading of disease activity varied from 0 to 4 depending on the degree of portal and/or lobular inflammation and necrosis. Staging of fibrosis was also based on 0 - 4 scale according to the extent of portal and periportal fibrosis.
- iii.) The degree of dysplasia was assessed following the criteria proposed by the International Working Party to define low and high grade dysplasia (International Working Party, 1995).

### *In situ* hybridization (ISH)

ISH was performed using a commercially synthesized biotinylated probe (Pharmacia Biotech, NJ, USA). It is an oligo-nucleotide probe, with a 50 base sequence (5'CGGGGCACTCGCAAGCACCCCTATCAGGCAGTACCACAAGG CCTTTCGCGA-3'). The technique of ISH was performed by using the supersensitive ISH kit (Biogenex, CA, USA) according to the method of Felgar et al. (1996). The specificity of the technique was assessed by:

- i.) Use of negative control tissue from 10 patients with no HCV infection.
- ii.) Use of a positive control tissue from a case that was known to be positive for HCV-RNA in the liver tissue by PCR.
- iii.) Pretreatment of the tissue sections with RNase before hybridization.
- iv.) Omission of the probe in the hybridization solution to evaluate any potential endogenous peroxidase activity.

For analysis of the results, the degree of ISH positivity was semiquantitated according to the percentage of positive cells as: 1+ (< 10%), 2+ (10 - 50%), 3+ (> 50%).

**Table 1.** Histopathologic data of liver biopsies from 60 patients with chronic HCV hepatitis.

Histopathology	Number	%
<b>* HCV Criteria</b>	60	100
- Lymphoid aggregates	56	93.3
- Lobular lymphoid infiltrate	44	73.3
- Steatosis	40	66.7
- Bile duct damage	36	60.0
<b>* Grade of disease activity</b>		
0	0	0.0
1	20	33.3
2	28	46.7
3	10	16.7
4	2	3.3
<b>* Stage of Fibrosis</b>		
0	16	26.7
1	16	26.7
2	6	10.0
3	2	3.3
4	20	33.3
<b>* Dysplasia</b>		
0	52	86.7
LG	2	3.3
HG	6	10.0

\* LG, Low grade; \* HG, High grade.

### Statistical analysis

Chisquare and Fisher's exact tests were used to assess the significance of association between the ISH results and the various histopathologic features. Spearman and Pearson correlation coefficients were applied to assess the linearity between the degree of ISH positivity and both ALT and HCV RNA levels in the patients' sera. The grade of liver cell dysplasia was correlated to the degree of ISH positivity and the level of serum HCV RNA by using Pearson correlation coefficient.

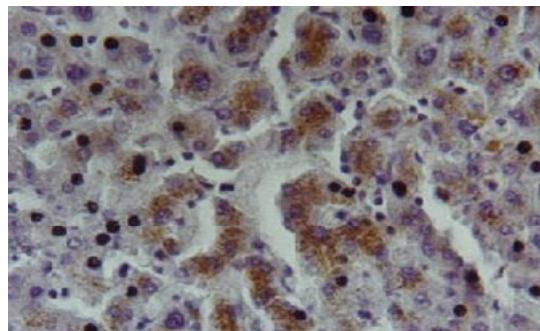
## RESULTS

### Histopathologic findings: Table 1

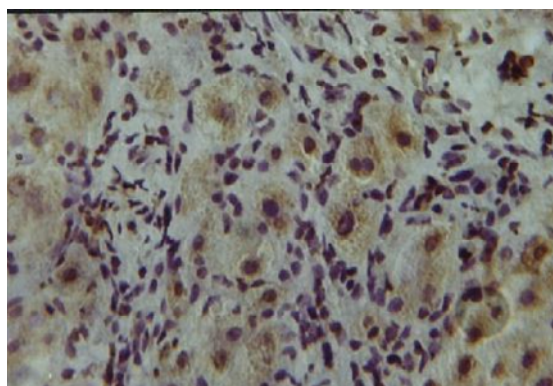
All liver biopsies obtained from the 60 patients with HCV infection showed the characteristic histologic features of HCV hepatitis. The most common feature was portal lymphoid aggregates (93, 3%) followed by lobular lymphocytic infiltrate (73.3%), steatosis (66.7%) and bile duct damage (60%). Furthermore, all specimens showed variable grades of inflammatory activity with grade 2 as the commonest (46.7%). Fibrosis was evident in 44 biopsies (73.3%) 20 of which had cirrhosis (stage 4 fibrosis). Eight liver specimens (13.3%) showed dysplasia, which was low grade in 2 cases and high grade in 6.

**Table 2.** *In situ* hybridization results of liver biopsies from 60 patients with chronic HCV hepatitis.

ISH Results	Number	%
0	36	60.0
1+	8	13.3
2+	6	10.0
3+	10	16.7



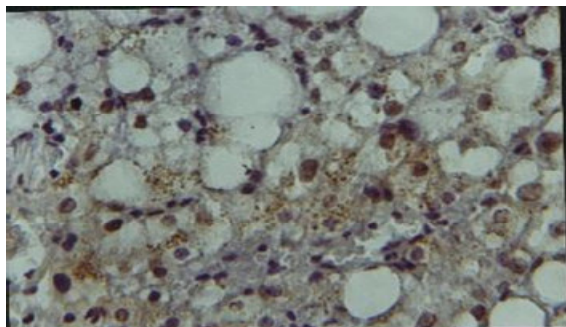
**Figure 1.** Liver biopsy from a patient with chronic HCV hepatitis showing strong positive cytoplasmic staining of hepatocytes for HCV RNA by *in situ* Hybridization (X 250).



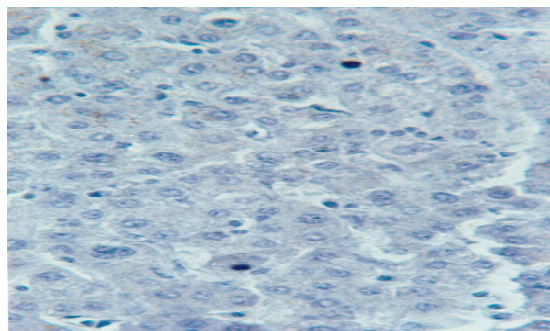
**Figure 2A.** Liver biopsy from a patient with chronic HCV hepatitis showing moderate positive cytoplasmic staining of hepatocytes for HCV RNA by *in situ* hybridization. Positive cells are seen within an area of piece-meal necrosis. (X 250).

### *In situ* hybridization (ISH) findings: Table 2

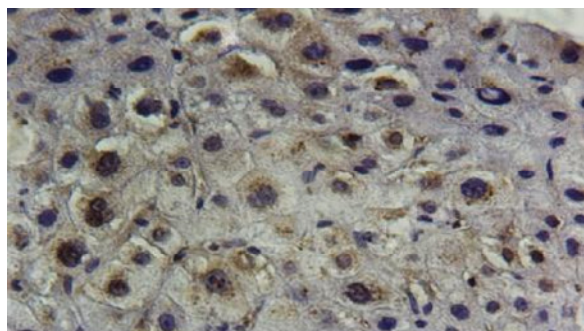
ISH labeling was observed in 24 out of the 60 liver biopsies (40%) under study. Positivity for HCV RNA was observed in the liver cells only as cytoplasmic brown granular staining (Figure 1). HCV-positive hepatocytes were found in areas of piece meal necrosis (Figure 2A), in areas with steatosis (Figure 2B) or in areas showing liver



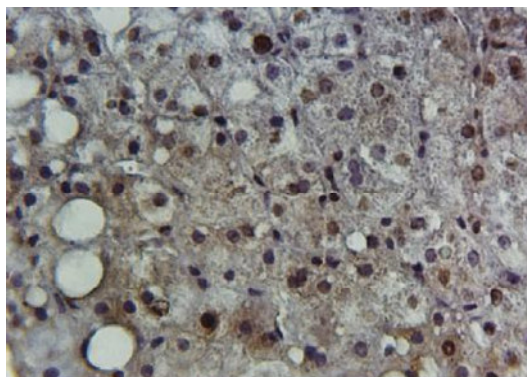
**Figure 2B.** Liver biopsy from a patient with chronic HCV hepatitis showing hepatocytes positive for HCV RNA distributed in the area of steatosis (X 250).



**Figure 4.** Liver biopsy from a negative control showing no HCV-RNA signals by *in situ* hybridization (X 250).

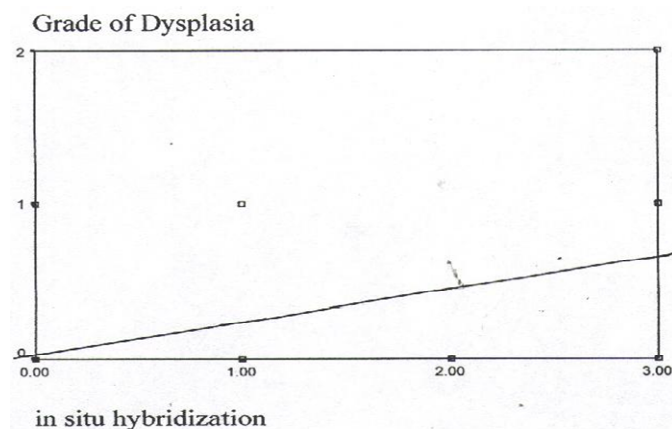


**Figure 2C.** Liver biopsy from a patient with chronic HCV hepatitis showing dysplastic liver cells with cytoplasmic positivity for HCV RNA by *in situ* hybridization (X 250).



**Figure 3.** Liver biopsy from a patient with chronic HCV hepatitis showing weak staining of the cytoplasm and nuclei of hepatocytes for HCV RNA by *in situ* hybridization (X 250).

cell dysplasia (Figure 2C). Occasional nuclear staining was also seen in 6 of the 24 positive cases (Figure 3). No HCV RNA signals could be detected in the mono-nuclear cells, bile duct epithelium or other sites.



**Figure 5.** Scatter diagram showing a statistically significant positive linear association between the degree of positivity for HCV RNA by *in situ* hybridization and the grade of dysplasia ( $r = 0.49$ ,  $P < 0.0001$ ).

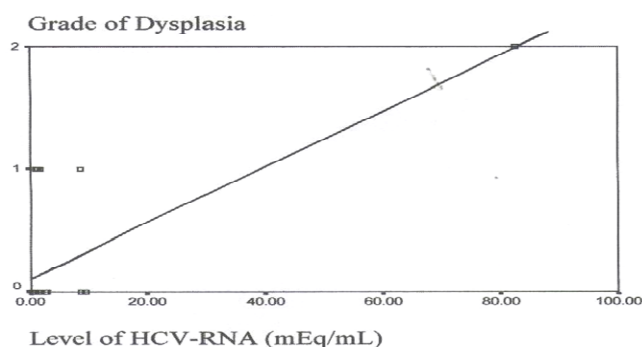
Negative hybridization results were obtained in the liver biopsies from the 10 patients used as negative controls (Figure 4). No hybridization was observed after RNase treatment of the tissue sections.

### Relationships between ISH results and other factors

There was no statistically significant association between ISH finding and either patients' sex, age or histologic features of HCV hepatitis, grade of inflammation or stage of fibrosis. At the same time, no correlation could be obtained between the degree of HCV positivity and either the levels of ALT or serum HCV RNA levels.

The only significant relationship was the correlation between the extent of HCV RNA positivity and the grade of liver cell dysplasia ( $r = 0.49$ ,  $P < 0.0001$ ) (Figure 5). The latter was also significantly correlated to the level of serum HCV RNA ( $r = 0.75$ ,  $P < 0.0001$ ) (Figure 6).





**Figure 6.** Scatter diagram showing a statistically significant positive linear association between the level of serum HCV RNA and the grade of dysplasia ( $r = 0.75$ ,  $P < 0.0001$ ).

## DISCUSSION

HCV is encountered worldwide where prevalence among blood donors in USA, Europe, Africa and Japan ranges between 0.01 to 1.5% (Van der Poel et al., 1994). Unfortunately, several international documented reports have shown that the prevalence of HCV among Egyptian blood donors is 10 to 15 times higher than the worldwide prevalence (Abdel-Wahab et al., 1994; Arthur et al., 1997; Abdel et al., 2000). The possible role of schistosomiasis in promoting HCV infection among Egyptian patients has been discussed previously (Helal et al., 1998). Follow up studies revealed that 20 - 30% of HCV infected patients develop cirrhosis (Yano et al., 1996; Seeff et al., 1992). Other studies reported that HCV infection is a major factor for the development of hepatocellular carcinoma (Blum, 1994; Trerisani et al., 1995). By combining the high prevalence of HCV infection among Egyptians and the fatal complications of this disease, it becomes clear that HCV infection represents a major health problem in Egypt. Therefore, we found it necessary to direct the clinicopathologic and molecular biology research to this important area in order to understand the molecular mechanisms of HCV pathogenesis and establish a reliable diagnostic policy that helps to evaluate the severity of the disease and predicts its prognosis.

This study applied the recently described technique for detection of HCV RNA in the liver tissue by *in situ* hybridization (ISH) (Felgar et al., 1996). Although the sensitivity of this technique was 60% as published by Felgar et al. (1996), we preferred this technique because it has two main advantages. First, it can be used on formalin-fixed tissue. Second, it uses non-radioactive biotinylated probes and streptavidin-conjugated horseradish peroxidase-based detection system which requires short hybridization time. Therefore, this method has the potential privilege of being rapid, simple and can be performed in routine pathology laboratories as a confirmatory tool for the diagnosis of active HCV infection.

In the present study, HCV RNA was not detected in all liver biopsies from patients who were tested positive for HCV RNA in their sera. This finding, which is consistent with other studies (Haruna et al., 1993; Felgar et al., 1996), can be explained by the possibility that the tissue sections (in cases with positive serum HCV RNA) might be taken from noninfected areas and accordingly, these areas showed no HCV RNA-positive hepatocytes (Felgar et al., 1996). Another assumption is that the amount of HCV RNA in the liver tissue might be too small to be detected by ISH without amplification. This assumption was supported by Haruna et al. (1993) who found that while HCV RNA could be detected by RT-PCR in all 7 liver biopsies studied, HCV RNA positive hepatocytes were demonstrated in 3 specimens only by ISH.

Regarding the cell types infected by HCV; ISH signals were exclusively detected in the liver cells. No staining was found in the bile duct epithelium, sinusoidal cells or the infiltrating mononuclear cells. This hepatocellular distribution of the HCV RNA was in agreement with other studies (Tanaka et al., 1993; Haruna et al., 1993; Kojima et al., 1996; Cho et al., 1996; Felgar et al., 1996; Angello et al., 1998; Gosalvez et al., 1998). Hepatocytes showed cytoplasmic localization of the viral signals in all positive cases. Additional focal nuclear staining was noted in 6 of the positive specimens. This occasional nuclear positivity was also detected by other investigators (Lamas et al., 1992; Cho et al., 1996; Angello et al., 1998; Gosalvez et al., 1998). The reasons for the nuclear staining observed in this study were not obvious. However, Lamas et al. (1992) and Gasalvez et al. (1998) suggested that HCV has a nuclear phase in its replication cycle as other flaviviruses. Conversely, Angello et al. (1998) believed that the nuclear positivity may be false because cytoplasmic staining for HCV was also present and confocal microscopy showed that the staining which appears to be nuclear by conventional microscopy may be due to cytoplasmic staining overlying the nucleus (Barba et al., 1997). Moreover, electronmicroscopic immunolocalization studies using anti-NSS peptide HCV antibodies showed labeling of the cytosol and failed to reveal nuclear localization of this antigen (Tsutumi et al., 1994).

The most important objective in the current study was the correlation of ISH results with the various histopathologic and biochemical data. In consistence with other reports (Haruna et al., 1993; Chang et al., 2000; Rodriguez-Ingo et al., 1999; Nouri et al., 1993), no significant relationship could be obtained between the results of ISH and grade of disease activity, stage of fibrosis or other individual criteria of HCV. This lack of relation between HCV RNA in the liver and hepatic injury might suggest that the accumulation of HCV RNA may represent some form of viral latency or inactivity in the infected liver tissue. In a recent study using ISH, Chang et al. (2000) detected both genomic and replicate of HCV RNA in the liver biopsies from infected patients. They demonstrated

that the hepatocellular injury significantly correlated with the levels of replicate of HCV RNA but not with genomic HCV RNA. Accordingly, it has been proposed that active replication of HCV in the liver tissue is the determining factor for hepatic pathology.

The most striking and interesting observation in the present work was that although HCV RNA levels in the liver and the patient's sera did not correlate with any histologic data of liver injury, both parameters were significantly correlating with the grade of dysplasia. To the best of our knowledge, the relationship between HCV RNA viral load in the liver and/or serum and liver cell dysplasia was not previously reported in the literature. Haruna and associates (Haruna et al., 1993) proposed that the pathogenesis of hepatocellular carcinoma associated with HCV infection may be caused by either continuous regeneration of hepatocytes due to chronic necro-inflammatory process, or HCV may have a direct carcinogenic effect on infected liver cells. Since liver cell dysplasia was claimed to be a precursor for the development of hepatocellular carcinoma (International Working Party, 1995; Bannasch, 1996), the significant correlation between HCV RNA positivity in the liver and the grade of dysplasia reported in this study might support the hypothesis that HCV might have direct oncogenic effect on the liver cells. Yet, this hypothesis deserves further investigation, because if it is confirmed, treatment with interferon should be extended to patients having no active hepatic pathology despite chronic HCV infection (Haruna et al., 1994). Recently, Lei et al. (2002) investigated the frequency of HCV infection in hepatocellular carcinoma tissue by means of immunohistochemistry and *in situ* hybridization. On the other hand, Donato et al. (2001) compared the degree of liver cell proliferation and dysplasia in hepatitis B and C virus cirrhotics. The association between dysplasia and HCV-RNA in the liver tissue was not concerned in both studies. Thus, it is obvious that the current work is unique in focusing on the correlation between the degree of liver cell dysplasia and the level of HCV-RNA in both the serum and liver tissue in patients with HCV hepatitis.

The relationship between HCV-RNA results using ISH and serum ALT levels is controversial. Although some authors could obtain a significant association between the levels of HCV-RNA in the liver by ISH and the levels of serum ALT (Cho et al., 1996; Morimoto et al., 1997), we and others (Haruna et al., 1993; Kojima et al., 1996) could not achieve such an association. The lack of correlation between HCV RNA in the liver and serum ALT levels might suggest that the direct cytopathic effects of HCV plays a minor role in the pathogenesis of chronic HCV infection (Kojima et al., 1996).

In the present study, the degree of tissue positivity for HCV RNA was not significantly correlated with the serum viral load as measured by b-DNA technique. Although this finding was consistent with Chang et al. (2000), it

contrasts with the findings of other investigators (Gosalvez et al., 1998; Rodriguez-Ingo et al., 1999; Morimoto et al., 1997). In fact, the absence of a significant association between the levels of viral RNA in the serum and the degree of liver RNA positivity was mostly attributed to the negative ISH results in patients positive for serum HCV RNA. Therefore, the lack of relationship between the levels of viral load in the serum and liver tissue might be due to small number of infected hepatocytes which were missed by ISH without prior amplification (Haruna et al., 1993; Felgar et al., 1996). Alternatively, an extrahepatic site of HCV replication was suggested to explain the continuous viremia in the absence of HCV RNA in the liver (Negro et al., 1992).

In conclusion, the current study has demonstrated that HCV RNA detected by ISH in HCV infected patients was related neither to the extent of liver injury, the levels of ALT nor the levels of viremia. More importantly, the degree of HCV RNA positivity in the liver tissue as well as its level in the serum was significantly correlated with the grade of liver cell dysplasia. Thus, a direct carcinogenic effect of HCV on liver cells seems more likely. Undoubtedly, more large scale molecular biologic studies are needed not only to confirm the present data, but also to investigate the mechanism of HCV-induced liver damage and its role in the development of hepatocellular carcinoma.

## REFERENCES

- Abdel Aziz F, Habib M, Mohamed M, Abdel Hamid M, Gamil F, Madkam S, Esmat G, Thomas DL, Strickland GT (2000). Hepatitis C virus (HCV) infection in a community in the Nile Delta: population description and HCV prevalence. *Hepatology*. 32: 111-115.
- Abdel-Wahab MF, Zakaria S, Kamel M, Abdel Khaliq MK, Mabrouk MA, Salma H, Oliva H, Carreño V (1994). High prevalence of Hepatitis C infection among risk groups in Egypt. *Am. J. Trop. Med. Hyg.* 51: 563-567.
- Angello V, Abel G, Kinight G, Muchmore E (1998). Detection of widespread hepatocyte infection in chronic hepatitis C. *Hepatology*. 28: 573-584.
- Arthur RR, Hassan NF, Abdallah M, El Sharkawy MS, Hackbart BG, Imam IZ (1997). Hepatitis C antibody prevalence in blood donors in different governorates in Egypt. *Trans. R. Soc. Trop. Med. Hyg.* 91: 271-274
- Bannasch P (1996). Pathogenesis of hepatocellular carcinoma: Sequential cellular, molecular and metabolic changes. *Prog. Liver Dis.* 14: 161-197.
- Barba G, Happer F, Harodat, Kohara M, Goulinet S, Matzurra Y, Eder G, Schaff Z, Chapman MJ, Miyamura T, Brechot C (1997). Hepatitis C virus core protein shows a cytoplasmic localization and associates to cellular lipid storage droplets. *Proc. Natl. Acad. Sci. USA.* 94: 1200-1205.
- Blum HE (1994). Does hepatitis C virus cause hepatocellular carcinoma? *Hepatology*. 19: 251-258.
- Castillo I, Bartolone J, Quiroga JA, Carreno V (1992). Comparison of several PCR procedures for detection of serum HCV RNA using different regions of the HCV genome. *J. Virol. Methods.* 38: 71-80.
- Chang M, Marquardt A, Wood B, Williams O, Cotler S, Tarylor S, et al. Carithers RL Jr, Gretch DR (2000). *In situ* hybridization of hepatitis C virus replicative-intermediate RNA in hepatic tissue and its correlation with liver disease. *J. Virol.* 74: 944-955.

- Chemello L, Bonetti P, Cavalletto L, Talato F, Donadon V, Casarin P, Belussi F, Frezza M, Noventa F, Pontisso P (1995). Randomized trial comparing three different regimens of alpha 2a-interferon in chronic hepatitis C. *Hepatology*. 22: 700-706.
- Chn HW, Dash S, Gerber MA (1994). Genomic and replicative hepatitis virus RNA sequences and histologic activity in chronic hepatitis C. *Hum. Pathol.* 25:160-163.
- Cho SW, Hwang SG, Han DC, Jin SY, Lee MS, Shin CS, et al. Lee DW, Lee HB. I (1996). *In situ* detection of hepatitis C virus RNA in liver tissue using a digoxinin-labeled probe created during a polymerase chain reaction. *J. Med. Virol.* 48: 227-233.
- de Lucas S, Bartolome J, Rodrigues Inigo E, Casqueiro M, Millan A, Moreno M, Oliva H, Carreño V (2001). Distribution of hepatitis C virus infection in liver biopsies from children and adults with chronic hepatitis C. *J. Med. Virol.* 64: 1-5.
- De Moliner L, Pontisso P, DeSalvo GL, Cavalletto I, Chemello L, Alberti A (1998). Serum and liver HCV RNA levels in patients with chronic hepatitis C: Correlation with clinical and histological features. *Gut*. 42: 856-860.
- Donato MF, Arosio E, Monti V, Fasani P, Prati D, Sangiovanni A, Ronchi G, Colombo M (2002). Proliferating cell nuclear antigen assessed by a computer-assisted image analysis system in patients with chronic viral hepatitis and cirrhosis. *Dig. Liver Dis.* 34(3):197-203.
- Felgar RE, Montone KT, Furth EE (1996). A rapid method for detection of hepatitis C virus RNA by *in situ* hybridization. *Mod. Pathol.* 9:696-702.
- Fong TS, Shindo M, Feinstone SM, Hoofnagle JH, Di Bisceglie AM (1991). Detection of replicative intermediates of hepatitis C viral RNA in liver and serum samples of patients with chronic hepatitis C. *J. Clin. Invest.* 88: 1058-1060.
- Gastaldi M, Massacrier A, Planells R, Schlupp A, Bartolomei I, Bowliere M, Quilici F, Fiteni J, Mazzella E, Cau P (1995). Detection by *in situ* hybridization of hepatitis C virus positive and negative RNA strands using digoxinin-labeled c RNA probes in human liver cells. *J. Hepatol.* 23:509-518.
- Gerber MA (1994). Pathology of hepatitis C FEMS. *Microbiol. Rev.* 14: 205-210.
- Gosalvez J, Rodriguez-Inigo E, Ramiro-Diaz J, Bartolone J, Tomoas J, Oliva H, Carreno V (1998). Relative quantification and mapping of hepatitis C virus by *in situ* hybridization and digital image analysis. *Hepatology*. 27: 1428-1434.
- Haruna Y, Hayash: N, Kamada T, Hytiroglou P, Thung SN, Gerber MA (1994). Expression of hepatitis C Virus in hepatocellular carcinoma. *Cancer*. 73: 2253-2258.
- Haruna Y, Hayashi N, Hriamatsu N, Takehara T, Hagiware H, sasaki Y, Kashara A, Fusamoto H, kamada T (1993). Detection of hepatitis C virus RNA in liver tissue by an *in situ* hybridization technique. *J. Hepatol.* 18:96-100.
- Helal T El. A, Daniel MF, Ahmed HF (1998). The relationship between hepatitis C virus and Schistosomiasis: Histopathologic evaluation of liver biopsy specimens. *Hum. Pathol.* 29: 743-749.
- International Working Party, (1995). Terminology of nodular hepatocellular lesions. *Hepatology*. 22: 983-993.
- Kojima S, Tanaka Y, Enomoto N, Marumo F, Sato C (1996). Distribution of hepatitis C virus RNA in the liver and its relation to histopathological changes. *Liver*. 16: 55-60.
- Kuo G, Choo QL, Alter HJ, Gitnick G, Redeker AG, Purcell RH, Mivamura T, Dienstag JL, Alter MJ, Stevens CE (1989). An assay for circulating antibodies to a major etiologic virus of human non A, non B hepatitis. *Science* 244: 362- 364.
- Lamas E, Baccarini P, Housset C, Krensdor D, Brechot C (1992). Detection of hepatitis C virus (HCV) RNA sequences in liver tissue by *in situ* hybridization. *J. Hepatol.* 16: 219-223.
- Lei X, Zhao L, Liu C, Liu L, Zhou S, Wang J (2001). Detection of hepatitis C virus from hepatocellular carcinoma and its relationship to hepatocarcinogenesis. (Abstract) *Hua Xi Yi Ke Da Xue Xue Bao*. 32(2):183-187.
- Lok ASF, Gunaratnam NT (1997). Diagnosis of hepatitis C. *Hepatology*. 26: 48S-56S.
- Morimoto H, Kuroki T, Kobavashi K, Nomura S, Sakurai M (1997). A histopathological study on localization of hepatitis C virus RNA in liver of chronic hepatitis C. *Osaka Citv. Med. J.* 43: 153-171. (abstract)
- Negro F, Pacchioni D, Shinizu Y, Miller RH, Bussolati G, Purcell RH, Bonino F (1992). Detection of intra-hepatic replication of hepatitis C virus RNA by *in situ* hybridization and comparison with histopathology. *Proc. Natl. Acad. Sci.* 89: 2247-2251.
- Nouri Ariak T, Sallie D, Sanger GJ, Alexander H, Smith J, Byrne B, Portmann B, Eddleston AL, Williams R (1993). Detection of genomic and intermediate replicative strands of hepatitis C virus in liver tissue by *in situ* hybridization. *J. Clin. Invest.* 91: 2226-2234.
- Rodriguez-Ingo E, Bartolome J, de Lucas S, Manzarbeitia F, Pardo M, Arocema C, Gosálvez J, Oliva H, Carreño V (1999). Histological damage in chronic hepatitis C is not related to extent of infection in the liver. *Am. J. Pathol.* 154: 1877-1881.
- Sakanoto N, Enomoto N, Kurosaki M, Marumo F, Sato C (1994). Detection and quantification of hepatitis C virus RNA replication in the liver. *J. Hepatol.* 20: 593-597.
- Scheuer PJ (1991). Classification of Chronic viral hepatitis: a need for reassessment. *J. Hepatol.* 13: 372-374.
- Scheuer PJ, Ashrafzadeh P, Sherlock S, Brown, Dusheriko GM (1992). The Pathology of hepatitis C. *Hepatology*. 15: 567-571.
- Seeff IB, Buskell-Bales Z, Wright EC, Durako SJ, Alter HJ, Iber FL, Hollinger FB, Gitnick G, Knodell RG, Perrillo RP (1992). Long-term mortality after transfusion associated non-A, non-B hepatitis. *N. Engl. J. Med.* 327: 1906-1911.
- Sheuer PJ, Krawczyns K, Dhillon AP (1997). Histopathology and detection of hepatitis C virus in liver. *Springer Semin. Immunopathology* 19: 27-45.
- Tanaka Y, Enomoto N, Kojima S, Tang L, Goto M, Marumo F, Sato C (1993). Detection of hepatitis C virus RNA in the liver by *in situ* hybridization. *Liver*. 13: 203-208.
- Trerisani F, D'Intino PE, Carceni P, Pizzo M, Stefanini GF, Mazziotti A, Grazi GL, Gozzetti G, Gasbarrini G, Bernardi M (1995). Etiologic factors and clinical presentation of hepatocellular carcinoma: differences between cirrhotic and noncirrhotic Italian patients. *Cancer*. 75: 2220-2232.
- Tsubota A, Kumada H, Chayama K, Arase Y, Saitoh S, Koida I, Murashima N, Suzuki Y, Kobayashi M, Takaqi K, Kobayashi M, Ikeda K (1996). Relationship between pretreatment viremia level and response to interferon therapy in chronic hepatitis C differs in viral type 1 and 2 infections. *Dig. Dis. Sci.* 41: 1925-1932.
- Tsui W (1996). New Classification of Chronic hepatitis and more. *Adv. Anat Pathol.* 3: 64-70.
- Tsutumi M, Urashima S, Takada A, Date T, Tamaka Y (1994). Detection of antigens related to hepatitis C virus RNA encoding the NS5 regions in the livers of patients with chronic type C hepatitis. *Hepatology*. 19:265-272.
- Tuboto A, Chayama K, Ikeda K, Yasuji A, Koida I, Saitoh S, Hahimoto M, Iwasaki S, Kobavashi M, Hiromitsu K (1994). Factors predictive of response to interferon therapy in hepatitis C virus infection. *Hepatology*. 19: 1088-1094.
- Van der Poel CL, Cypens HT, Reesink HW (1994). Hepatitis C virus, six years on. *Lancet*. 344: 1475-1479.
- Weiner AJ, Kuo G, Bradley DW, Bonino F, Saracco G, Lee C, Rosenblatt J, Choo QL, Houghton M (1990). Detection of hepatitis C viral sequences in non-A, non-B hepatitis. *Lancet*. 1:1-3.
- Yamada G, Nishimoto H, Endou H, Doi T, Takahashi M, Tsuji T, Yoshizawa H, Nozawa M, Koji T, Nakane PK (1993). Localization of hepatitis C viral RNA and capsid protein in human liver. *Dig. Dis. Sci.* 38: 882-887.
- Yano M, Kumada M, Kage M, Ikeda K, Shimametsu K, Inoue O, Hashimoto E, Lefkowitz JH, Ludwig J, Okuda K (1996). The long term pathological evolution of chronic hepatitis C. *Hepatology* 23:1334-1340.